

# Symptomatic right carotid artery kink – a case report

L Mtimba,<sup>1,2</sup> VC Ntola,<sup>3,4</sup> E Ninise<sup>5,6</sup>

<sup>1</sup> Department of General Surgery, Faculty of Health Science, Walter Sisulu University, South Africa

<sup>2</sup> Life St Mary's Private Hospital, South Africa

<sup>3</sup> Department of General Surgery, Nelson R Mandela School of Medicine, University of KwaZulu-Natal, South Africa

<sup>4</sup> Life Entabeni Private Hospital, South Africa

<sup>5</sup> Department of Anaesthesia, Faculty of Health Science, Walter Sisulu University, South Africa

<sup>6</sup> Life St Mary's Private Hospital, South Africa

Corresponding author, email: vuyolwe@yahoo.com

## Summary

This case report details the management of a patient with a symptomatic right common carotid artery kinking, an uncommon condition and the first one to be managed at the authors' institution. We discuss the clinical significance and management of dolichoarteriopathies. The patient was managed successfully via open surgery.

**Keywords:** dolichoarteriopathy, carotid kink, carotid coil, carotid tortuosity

## Case presentation

A 66-year-old male presented with a two-year history of dizziness, associated with brief episodes of loss of vision. He experienced symptoms whenever he turned his head towards the side of the kink (right). The patient was initially seen by a private general surgeon, who then sent the patient to the author's private practice. The medical and surgical history was unremarkable. The neurological examination was unremarkable, except that he would feel dizzy and

collapsed when turning his head to the right side. Doppler ultrasound and computed tomography angiography (CTA) showed a right-sided common carotid artery (CCA) kink at the proximal segment (Figure 1).

The patient was admitted and scheduled for surgery. Under general anaesthesia, an incision along the medial border of the sternocleidomastoid muscle was made. The proximal CCA was found to have a significant kink (Figure 2) that resulted in luminal occlusion whenever the head was turned to the ipsilateral side. Prior to clamping of the CCA

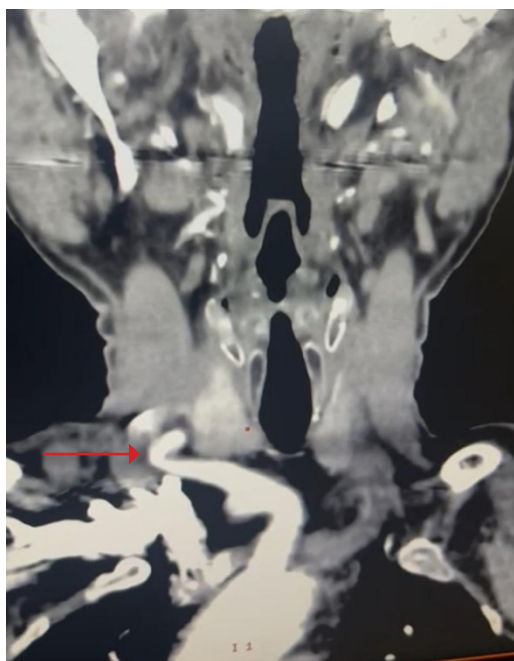


Figure 1: Coronal view of the computed tomography angiography. Red arrow shows the kinked right common carotid artery.

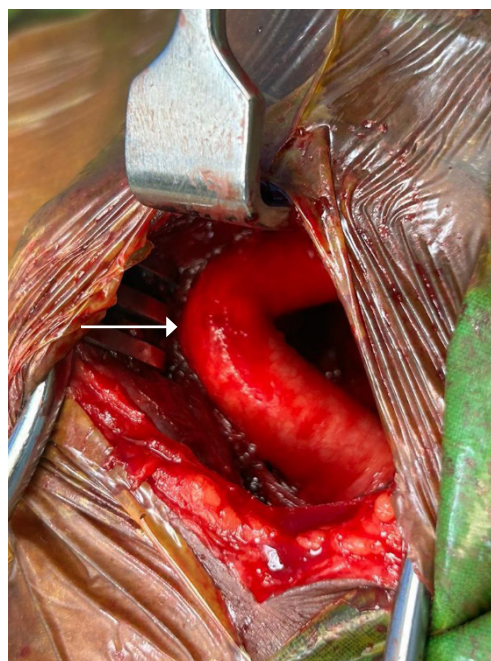


Figure 2: Intraoperative picture, the white arrow points at the common carotid artery kink.

the stump pressure was measured, and the mean arterial blood pressure was 52 mmHg. The clamping time was 14 minutes. A 3.5 cm kinked segment was resected, followed by a primary end-to-end anastomosis.

Post-surgery, the patient did well and his symptoms resolved. He had no neurological fallout and was discharged on the following day. He was reviewed after a month and was still symptom-free. The histological report showed focal degenerative changes of the media with atheroma formation.

## Discussion

The prevalence of morphological anomalies of the carotid artery is not well understood. These anomalies are collectively called dolichoarteriopathies. In the general population, morphological anomalies of the extracranial internal carotid artery range from 10–45%. These anomalies are kinking, tortuosity and coiling. The clinical significance of dolichoarteriopathies is related to the luminal narrowing leading to reduced cerebral blood flow. There is a paucity of information regarding CCA kinks, as most of the literature relates to extracranial internal carotid artery dolichoarteriopathies. There are two types of kinks – congenital and atherosclerotic. Congenital kinks become significant at an older age and most occur in the late 40s and early 50s.<sup>1-4</sup> Internal carotid artery (ICA) kink is considered a risk for cardiovascular events; recently, CCA kinking is also regarded as a predictor of cardiovascular events.<sup>5</sup>

Diagnosis is based on the clinical presentation and imaging which includes Doppler ultrasonography, CTA, magnetic resonance angiography (MRA) and digital subtraction angiography (DSA). Elongation and tortuosity of the ICA is common on imaging – in most cases it is asymptomatic. It can be associated with a bifurcation atherosclerosis plaque which is an indication for surgery, similar to that of carotid stenosis. Some patients have hemispheric or non-hemispheric symptoms.<sup>6,7</sup>

Surgical intervention is controversial. Due to the scarcity of this condition, there are no management guidelines. Management of symptomatic carotid kinking is surgical and entails resection of the kinked segment followed by end-to-end anastomosis. Carotid artery stenting may complicate the procedure in patients with severe carotid artery kinking.<sup>8</sup>

## Conflict of interest

The authors declare no conflict of interest.

## Funding source

No funding was required.

## Ethical approval

The authors declare that this submission is in accordance with the principles laid down by the Responsible Research Publication Position Statements as developed at the 2nd World Conference on Research Integrity in Singapore, 2010. Prior to commencement of the study ethical approval was obtained from the University of KwaZulu-Natal Biomedical Research Ethics Committee: BREC/00003897/2022.

## ORCID

L Mtimba  <https://orcid.org/0009-0003-2000-4914>

VC Ntola  <https://orcid.org/0000-0002-9667-1591>

E Ninise  <https://orcid.org/0009-0000-4922-7159>

## REFERENCES

1. Di Pino L, Franchino AG, Costa S, et al. Prevalence and morphological changes of carotid kinking and coiling growth: An echo-colour Doppler study of 2856 subjects between 0 to 96 years. *Int J Cardiovasc Imaging*. 2021;37:479-84. <https://doi.org/10.1007/s10554-020-02014-0>.
2. Amidzic A, Tiro N. Kinking of bilateral internal carotid arteries as cause of cognitive dysfunction. *Med Arch*. 2020;74(1):58. <https://doi.org/10.5455/medarh.2020.74.58-60>.
3. Sacco S, Totaro R, Baldassarre M, Carolei A. Morphological variations of the internal carotid artery: Prevalence, characteristics and association with cerebrovascular disease. *Int J Angiol*. 2007;16(02):59. <https://doi.org/10.1055/s-0031-1278249>.
4. Beigelman R, Izaguirre AM, Robles M, et al. Are kinking and coiling of carotid artery congenital or acquired? *Angiology*. 2010;61(1):107-12. <https://doi.org/10.1177/0003319709336417>.
5. Lwai-Takano M, Watanabe T, Ohira T. Common carotid artery kinking is a predictor of cardiovascular events: A long follow-up study using carotid ultrasonography. *Echocardiography*. 2019;36(12):2227-33. <https://doi.org/10.1111/echo.14536>.
6. Grego F, Lepidi S, Cognolato D, Frigatti P. Rationale of the surgical treatment of carotid kinking. *J Cardiovasc Surg*. 2003;44(1):79.
7. Yu J, Qu L, Xu B, et al. Current understanding of dolichoarteriopathies of the internal carotid artery: A review. *Int J Med Sci*. 2017;14(8):772. <https://doi.org/10.7150/ijms.19229>.
8. Erdinç İ, Öztaş DM, Yıldız CE, Uğurlucan M. Simultaneous treatment of carotid artery stenosis and kinking with regional cervical block. *Turk J Vasc Surg*. 2020;29(1):55-8. <https://doi.org/10.9739/tjvs.2020.172>.