

Massive jejunal gastrointestinal stromal tumour bleed – a case report

IN Palkowski,¹  S Visagie,¹ M Malik² 

¹ General Surgery, George Regional Hospital, South Africa

² General Surgery, Groote Schuur Hospital, South Africa

Corresponding author, email: ivan.palkowski@westerncape.gov.za

Summary

We present a rare case of a massive gastrointestinal bleed from a gastrointestinal stromal tumour (GIST) originating from the jejunum. GISTs make up only 0.1–3% of all gastrointestinal neoplasms and typically present as an occult or chronic gastrointestinal bleeding. Acute gastrointestinal bleeding from the small bowel is uncommon and can be a challenging diagnosis to make.

Keywords: gastrointestinal stromal tumour, massive gastrointestinal bleed, jejunum

Case report

A 35-year-old male with no comorbidities presented to the emergency unit with a 12-hour history of passage of significant amount of fresh blood per rectum. There was no history of vomiting. The patient denied use of nonsteroidal anti-inflammatory drugs, smoking, recreational drugs, recent alcohol use or use of anticoagulation therapy. He had no history of previous gastrointestinal bleeding, and no prior endoscopy had been performed.

Clinically the patient had hypovolemic shock with a low haemoglobin (Hb) of 4.8 g/dL (normal values 13.5–17.5 g/dL for adult male). There were no clinical features of liver failure. His abdomen was soft and there was fresh blood on rectal examination. No haemorrhoids or masses were felt.

Arterial blood gas analysis revealed an uncompensated metabolic acidosis (pH 7.28, bicarbonate (HCO₃⁻) 11 mmol/l, lactate 9.0 mmol/l, base excess (BE) -15.5 mmol/l and PCO₂ 3.2kPa) (normal ranges pH 7.35–7.45, HCO₃ 22–26 mmol/l, lactate < 2 mmol/l, BE -2 – +2 mmol/l and pCO₂ 4.7–6.0 kPa respectively).

The patient was resuscitated with crystalloids and blood products over four hours with a moderate improvement in his hemodynamic status and blood gas analysis. A total of 4 units of packed red cells and 4 units of fresh dried plasma were given.

An urgent upper endoscopy was performed up to the second part of the duodenum where no source of bleeding was found. The patient was transferred to the intensive care unit (ICU) for close observation and planned for colonoscopy during daytime hours if the patient remained stable.

The ICU nurse reported passage of blood clots and bright red blood per rectum. Furthermore, the patient became hemodynamically unstable. A full blood count revealed a Hb 6.4 g/dL, platelets of 40 x 10⁹/l (normal values 150–400 x10⁹/l) and a normal white cell count.

The patient was again resuscitated over 4 hours with blood products consisting of packed red cells, fresh dried plasma,

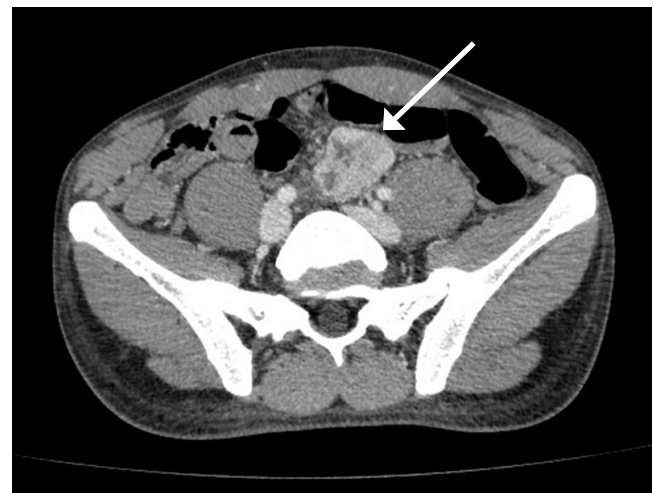


Figure 1: Contrasted CT of the abdomen demonstrating a small bowel mass (white arrow)

platelets and cryoprecipitate. There was an appropriate response to the resuscitation with improvement in his hemodynamic status.

He was transferred to the operating theatre for an urgent repeat upper endoscopy and lower endoscopy. The upper endoscopy again revealed no source of bleeding up to D2. The lower endoscopy up to the descending colon revealed red blood throughout the colon but no source of bleeding.

An urgent contrasted abdominal computerised tomography (CT) demonstrated a proximal small bowel mass (Figure 1).

The patient was scheduled for an exploratory laparotomy where a jejunal mass was found and resected to macroscopically clear margins. An end-to-end anastomosis was performed with a running 2/0 vicryl suture. Postoperatively, the patient was transferred to the ICU.

No further episodes of gastrointestinal bleeding were reported postoperatively. He was transferred to the general ward on the first postoperative day and discharged home on

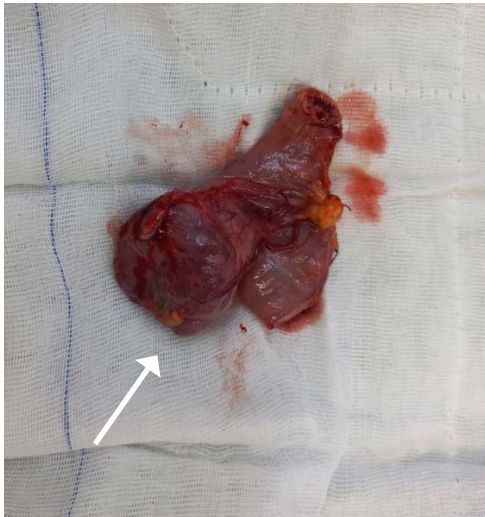

Figure 2: Specimen photograph demonstrating resected small bowel mass (white arrow)

the third postoperative day. He was planned for follow-up at the surgical outpatient department for clinical review and histology results in one week.

Histology of the resected small bowel showed a gastrointestinal stromal tumour (GIST). The size of the tumour was 3.9 cm with a mitotic rate of one per 5 mm². The margins were clear by more than 2 cm. The tumour was classified as low risk based on these histological values and there was no indication for adjuvant imatinib.

The patient was seen on the planned follow-up visit and he was doing clinically well with no further gastrointestinal bleeding reported.

Discussion

Gastrointestinal bleeding is a common surgical emergency and arises from either the upper gastrointestinal (above the ligament of Treitz) or lower gastrointestinal tract.

Massive gastrointestinal bleeding is a life-threatening surgical emergency characterised by hypotensive shock requiring early recognition and resuscitation usually with use of blood products.¹ No consensus on the formal definition exists currently.

The incidence of upper gastrointestinal bleeding is approximately 80 to 150 per 100 000 population and the estimated mortality rate 2% to 10%.² Common causes for massive upper gastrointestinal bleeding include peptic ulcer, duodenal ulcer and oesophageal varices. The most common causes for lower gastrointestinal bleeding include diverticulosis and arteriovenous malformations.¹

Acute management consists of adequate fluid and blood resuscitation, coagulation control and endoscopy within the first 24 hours with the aim to identify the source of haemorrhage and control the bleeding.^{1,3}

Bleeding from the small intestine is a rare occurrence, contributing to only about 5–10% of all cases of gastrointestinal bleeding.⁴

Angiodysplasia of the small bowel account for up to 40% of small intestinal bleeding. Other potential causes include tumours (both benign and malignant), polyps, Crohn's disease, Meckel's diverticulum and ulcers.⁵

Massive gastrointestinal bleeding from a jejunal GIST is very rare with only a few cases reported.⁵

GISTs are the most prevalent mesenchymal tumours found in the digestive tract, yet they make up only 0.1–3% of all gastrointestinal neoplasms.⁵ These tumours most commonly manifest through acute or chronic gastrointestinal bleeding, often leading to symptomatic anaemia in affected patients.⁵

GISTs most frequently develop in the stomach (60–70%) and small intestine (25–35%). Less commonly, they originate in the oesophagus (2–3%), while rarer occurrences are found in the colon, rectum, or appendix (5%).⁶

Bleeding from the small intestine can be a challenging diagnosis to make as this area is not accessible by standard endoscopy.⁵

Modalities for examination of the small bowel include video capsule endoscopy and push enteroscopy.³ However, in our case, these modalities were unavailable but would also not have been indicated as the patient was hemodynamically unstable.³

If upper and lower endoscopy fail to identify the source of gastrointestinal bleeding, contrasted tomography angiography can be considered.⁷

The appearance of GISTs varies based on their size and location, but they typically present as rounded soft tissue masses originating from the wall of a hollow organ, most often the stomach. These tumours may grow inward into the lumen or outward beyond the organ wall. In the small intestine, they predominantly exhibit an exoenteric growth pattern, characterised by a significant extraluminal component.⁶ Gastrointestinal bleeding results from tumour perforation through the mucosa.

In cases where there is high volume bleeding and hemodynamic instability despite adequate resuscitation, an exploratory laparotomy should be performed.⁷

Curative treatment of GIST involves complete surgical excision with negative margins, without the need for lymph node dissection.⁸

Several factors influence the risk of recurrence in resected GISTs, including tumour size, mitotic rate, primary site, and the occurrence of tumour rupture.⁹ Adjuvant imatinib is recommended to GISTs that are scored as high risk for recurrence.⁹

Studies suggest that gastrointestinal bleeding may be an independent risk factor for recurrence, highlighting the need for adjuvant treatment with imatinib in these patients.^{10,11}

Conflict of interest

The authors declare no conflict of interest.

Funding source


No funding source to be declared.

Ethical approval

Ethical approval granted from research ethics committee. University of Cape Town, Faculty of Health Sciences, Human Research Ethics Committee (Ref: 157/2025)

ORCID

IN Palkowski  <https://orcid.org/0000-0001-8641-2265>

M Malik  <https://orcid.org/0009-0004-2077-1133>

REFERENCES

1. Massive gastrointestinal bleeding - international emergency medicine education project [Internet]. [cited 2025 Feb

- 24]. Available from: <https://iem-student.org/massive-gastrointestinal-bleeding/>.
2. Stanley AJ, Laine L. Management of acute upper gastrointestinal bleeding. *BMJ*. 2019;364:1536. <https://doi.org/10.1136/bmj.1536>.
 3. Redondo-Cerezo E, Tendero-Peinado C, López-Tobaruela JM, et al. Risk factors for massive gastrointestinal bleeding occurrence and mortality: a prospective single-center study. *Am J Med Sci*. 2024;367(4):259-67. <https://doi.org/10.1016/j.amjms.2024.01.012>.
 4. Gerson LB, Fidler JL, Cave DR, Leighton JA. ACG Clinical Guideline: diagnosis and management of small bowel bleeding. *Am J Gastroenterol*. 2015;110(9):1265-87. <https://doi.org/10.1038/ajg.2015.246>.
 5. Dualim DM, Loo GH, Rajan R, Nik Mahmood NRK. Jejunal GIST: Hunting down an unusual cause of gastrointestinal bleed using double balloon enteroscopy. A case report. *Int J Surg Case Rep*. 2019;60:303-6. <https://doi.org/10.1016/j.ijscr.2019.06.053>.
 6. Silverstone L, Gaillard F. Gastrointestinal stromal tumour. In: *Radiopaedia.org* [Internet]. *Radiopaedia.org*; 2009. Available from: <http://radiopaedia.org/articles/6758>.
 7. Kim BSM, Li BT, Engel A, et al. Diagnosis of gastrointestinal bleeding: a practical guide for clinicians. *World J Gastrointest Pathophysiol*. 2014;5(4):467. <https://doi.org/10.4291/wjgp.v5.i4.467>.
 8. Balachandran VP, DeMatteo RP. Gastrointestinal stromal tumours. *Adv Surg*. 2014;48(1):165-83. <https://doi.org/10.1016/j.yasu.2014.05.014>.
 9. Laurent M, Brahmi M, Dufresne A, et al. Adjuvant therapy with imatinib in gastrointestinal stromal tumours (GISTs): review and perspectives. *Transl Gastroenterol Hepatol*. 2019;4:24. <https://doi.org/10.21037/tgh.2019.03.07>.
 10. Liu Q, Li Y, Dong M, Kong F, Dong Q. Gastrointestinal bleeding is an independent risk factor for poor prognosis in GIST patients. *Biomed Res Int*. 2017;2017:1-6. <https://doi.org/10.1155/2017/7152406>.
 11. Mahmoud S, Salman H. Massive bleeding of a jejunal gastrointestinal stromal tumour: A rare case of a life-threatening presentation. *J Surg Case Reports*. 2020;2020(10). <https://doi.org/10.1093/jscr/rjaa355>.