

# Transoral endoscopic thyroidectomy via vestibular approach (TOETVA): initial experience

WM Mathe,  MZ Koto 

Sefako Makgatho Health Sciences University, South Africa

Corresponding author, email: [mathewinnie@yahoo.com](mailto:mathewinnie@yahoo.com)

**Background:** We present our first four thyroidectomies performed via endoscopic vestibular approach.

**Methods:** Retrospective data was collected for all four patients who had endoscopic thyroid surgeries performed at a single centre between November 2023 and September 2024. Information on patient demographics, surgical technique and postoperative outcomes was collected and reviewed.

**Outcomes:** All four patients had transoral endoscopic thyroidectomy vestibular approach (TOETVA) successfully completed; conversion to traditional trans-cervical incision was not required in any of the cases. All patients were females aged between 29 and 63. The average operative time for the procedure was 210 minutes. The blood loss was negligible; the average length of hospital stay was 24 hours. No drains were used. No recurrent laryngeal nerve or mental nerve injuries were noted. No patient required completion thyroidectomy, as the histopathological analysis showed benign thyroid nodules in all four cases.

**Conclusion:** TOETVA is a safe and viable option for thyroid surgery and should be routinely considered for patients who require thyroid surgery and are eligible for it. Careful patient selection and counselling are paramount to avoid undesirable outcomes. The procedure yields excellent outcomes when performed by an experienced laparoscopic and thyroid surgeon.

**Keywords:** thyroidectomy, thyroid cancer

## Introduction

Transoral endoscopic thyroidectomy vestibular approach (TOETVA), as it is known today, was first presented at the International Association of Endocrine Surgeons (IAES) held in Bangkok in 2015 by Angkoon Anuwong. Angkoon Anuwong's innovative work began in 2014 in a case series involving 60 patients.<sup>1</sup>

It has since been adopted by Americans and Europeans in an attempt to implement its widespread use. Its demand is predominantly for cosmetic reasons.

Minimally invasive surgery has become the gold standard for surgery worldwide. Thyroid surgery has also evolved in this aspect. The traditional post-thyroidectomy scar on the neck has a negative impact on the patient's quality of life, particularly impacting their clothing.<sup>2</sup> It is also important to remember that the incidence of thyroid malignancy is highest amongst women; they are therefore the most affected by this.<sup>3</sup>

These women often have to live with a permanent unsightly scar that negatively impacts their quality of life. In the era where cosmesis is a big concern for patients, especially women, endoscopic thyroidectomy offers patients the option of scarless thyroidectomy. There is currently no case reported in South Africa in the literature on TOETVA. We are reporting our first clinical experience in performing TOETVA in South Africa.

## Patients and methods

The procedure was done at a public hospital in Pretoria, South Africa. All patients included in this case series were above the age of 18. Four patients were admitted between November 2023 and September 2024 and selected for the vestibular approach. All patients had preoperative assessment, including thyroid function test, neck ultrasound, reported in Thyroid Imaging Reporting and Data Systems (TIRADS), and Fine Needle Aspiration (FNA), using the Bethesda score, with the exception of one patient who had a toxic adenoma where FNA was omitted.

Inclusion criteria were: patients above the age of 18; thyroid nodule less than 4 cm, up to Bethesda IV; and thyroid nodule less than 2 cm in a Bethesda V and VI. Exclusion criteria were: confirmed thyroid malignancy; previous open neck surgery; patients under 18 years; recurrent laryngeal nerve palsy; and bilateral thyroid disease.

## Operative technique

The patient is done under general anaesthesia with transnasal intubation. The patient is cleaned and draped in a supine position. A sandbag is placed in-between the shoulder blades and the neck hyperextended. A small abdominal swab is used to plug the oropharynx. A 10 mm incision is made 1 cm above the lower lip frenulum. Two 5 mm incisions are made on the right and left commissure of the mouth. A pocket is created with a swab, holding forceps in the absence of the Awunong blunt dissector and a 10 mm port inserted;

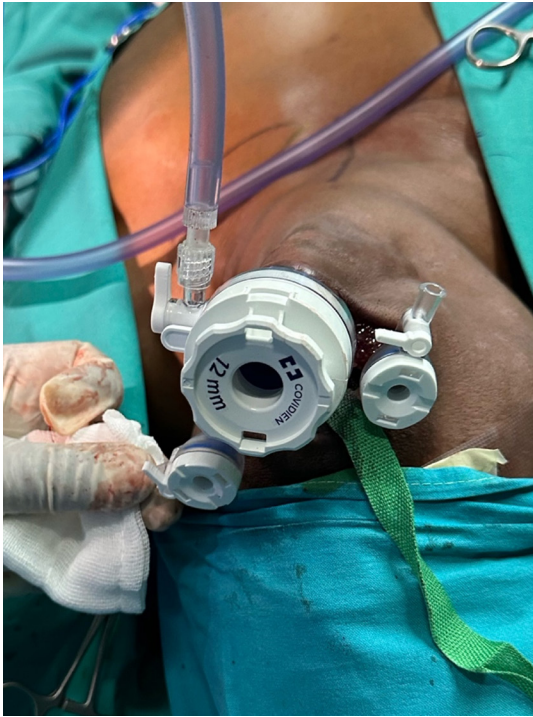

Figure 1: Port position; in this picture a 12 mm port was used instead of a 10 mm because of a shortage of ports

gas is inflated at a pressure of 8 mmHg. The 5 mm ports are inserted under vision. Dissection continues in the subplatysmal plane until the sternal notch. Strap muscles are divided and retracted laterally using a nylon 3/0.

Superior pole vessels are dissected and ligated with a laparoscopic ligasure. The external branch of the superior laryngeal nerve and the parathyroid gland are identified and preserved. The middle thyroid vein is identified and ligated. The thyroid lobe is then retracted medially to identify the inferior thyroid artery and recurrent laryngeal nerve. The gland is dissected off the trachea and the ligament of berry is divided using a ligasure. The inferior pole vessels are dissected and ligated. The specimen is retrieved using an endo bag. The specimen is retrieved from the 10 mm port; a 5 mm telescope is used on one of the 5 mm working ports to aid with specimen retrieval under vision. Haemostasis is achieved. The strap muscles are then reapproximated with intracorporeal suturing. The port sites are sutured with an interrupted chromic 3/0.

Intraoperative ultrasound and nerve monitor were not utilised.

## Results

The summary of all four patients' data is presented in Table I. All four patients were females between the age of 29 and 63 years. All four patients underwent lobectomy for diagnostic and cosmetic reasons. One patient had a toxic

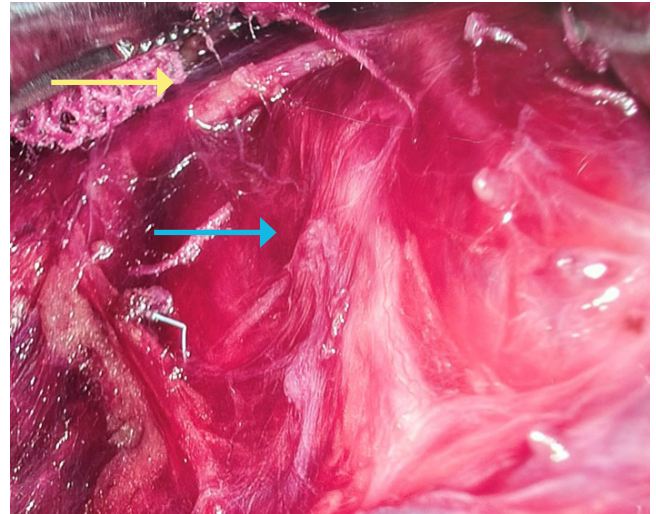


Figure 2: Identifying the recurrent laryngeal nerve on the left crossing behind the inferior thyroid artery (ITA) Yellow arrow – inferior thyroid artery (ITA), Blue arrow – recurrent laryngeal nerve (RLN)

thyroid adenoma, with a therapeutic indication. After 3 weeks, her thyroid function was normal, her Hb went from 9 g/dl to 10 g/dl and her overall quality of life had improved.

The mean length of hospital stay was 24 hours. All the TOETVA cases were carried out successfully with no need for conversion to conventional approach. In all the cases, the RLN and parathyroids were identified and preserved. The mean operative time was 210 minutes. No drains were used. No surgical complications were noted, including recurrent laryngeal nerve injuries. No bleeding, seroma, infection or need for reoperation was noted. No mental nerve injury

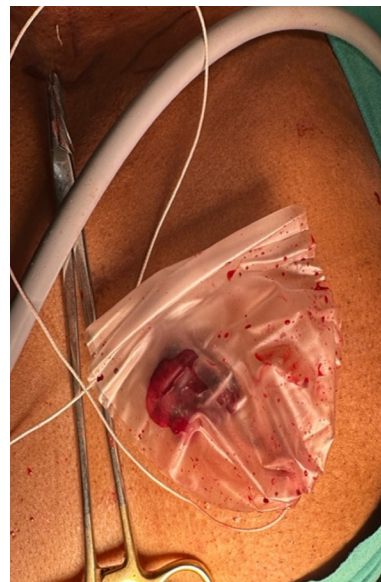

Figure 3: Retrieved specimen

Table I: Patient case and outcomes

Case n	Age (years)	Gender	Diagnosis	U/S	FNA	Time (min)	Histology	Size of nodule
1	63	F	L solitary thyroid nodule	TIRADS 3	Bethesda 1	180	nodular hyperplasia	2 x 2 cm
2	34	F	R solitary thyroid nodule	TIRADS 4	Bethesda 3	240	nodular hyperplasia	2 x 2 cm
3	29	F	L solitary thyroid nodule	TIRADS 4	Bethesda 3	240	nodular hyperplasia	2 x 1 cm
4	38	F	L solitary thyroid nodule	Unknown	Unknown	180	Follicular adenoma	2 x 2 cm

was found. All the patients were satisfied with the cosmetic results.

The histological analysis revealed nodular hyperplasia, benign disease in all four cases.

## Discussion

Thyroid surgery has really evolved with time, and thyroid surgeons are constantly trying to find new ways to improve patient outcomes.<sup>4</sup> Endoscopic thyroidectomy has been adopted to minimise the morbidity that is associated with thyroid surgery.<sup>5</sup> Different techniques have been adopted to minimise scarring during thyroid surgery, including robotic surgery and endoscopic surgery via cervical, axillary, anterior chest, breast, post auricular and transoral approaches.<sup>5</sup>

The advantages of TOETVA include excellent cosmetic outcomes and allow for magnified view of the thyroid structures. The drawbacks of the procedure are that it is technically difficult to perform with a steep learning curve.<sup>5</sup> The procedure has a learning curve of 15–25 cases.<sup>6</sup>

It also requires special instrumentation, which may not be readily available because of the cost in low- to middle-income countries. This procedure also has prolonged surgical time. Its routine use in a public sector hospital will be hindered by lack of resources.

There are sufficient data that point to the effectiveness and safety of TOETVA and the technique has been adopted worldwide. However, there is scarcity of data on this procedure performed in Africa.

This is, to our knowledge, the first case series on TOETVA in Africa.

The prevalence of clinically palpable thyroid nodules is 5% and 1% in women and men respectively. Thyroid cancer, which occurs in 7–15% of these patients, needs to be excluded.<sup>7</sup> The ATA guidelines support the use of diagnostic surgery in patients with suspicious nodules, Bethesda IV-V and patients with repeated non-diagnostic cytology results.<sup>7</sup>

The incidence of thyroid cancer is higher in women. The post-thyroidectomy scar seems to have a negative impact on their quality of life, particularly impacting their clothing, leaving most of these patients suffering from feelings of embarrassment as well.<sup>3</sup> A prospective cohort study by Arora et al. shows that most patients (75%) would prefer scarless thyroidectomy, if given an option to choose.<sup>8</sup>

Erman Alci et al. evaluated the public's perception of scar cosmesis after thyroidectomy, which seems to differ between cultures.<sup>9</sup> The South Korean group felt that they would feel more uncomfortable with a neck scar than the Turkish group. Female patients aged younger than 28 years and patients with a higher education level stated that they would be more uncomfortable with a neck scar. Some studies show a difference in perception between post-thyroidectomy patients and thyroid surgery naïve patients. The thyroid surgery naïve patients were more critical about a post-thyroidectomy neck scar.<sup>9</sup> De Vries et al. conducted a systemic review and meta-analysis to evaluate whether minimally invasive techniques like TOETVA are not inferior to conventional thyroidectomy.<sup>10</sup> He concluded that surgical outcomes in minimally invasive techniques are comparable with conventional thyroidectomy. Outcomes included complications and length of hospital stay; however, a longer operation time was noted with minimal invasive techniques such as TOETVA.<sup>10</sup> Sivakumar and Amizhthu had a case series with eleven patients with a less mean operative time

of 130 minutes, which can be attributed to higher population. The hospital stay was 3 days longer.<sup>11</sup>

Anuwong et al. retrospectively reviewed 200 patients who underwent TOETVA. His mean operative time was 97 minutes.<sup>12</sup> His inclusion criteria was much broader with bigger nodules, multinodular goitre, Graves disease and papillary microcarcinoma. He observed minimal postoperative complications that included a 1.5% mental nerve injury, transient hypoparathyroidism (17.5%) and hoarseness (4%). A total of 0.5% of postoperative haematomas were treated with open surgery. The same surgical technique was used with the exception of the use of intraoperative ultrasound and nerve monitor. We also used swabs to mop up the bed of the thyroid gland, which is not described by Anuwong et al.<sup>11</sup>

However one looks at it, scarless thyroidectomy is an option and should be made available to those who meet the requirements and have a desire for a scar-free surgery.

## Conclusion

The impact of post-thyroidectomy scar on patients' quality of life should not be ignored.

TOETVA is a safe and feasible surgical option and should be considered for all patients who require thyroid surgery and are eligible for the procedure. We recommend this to be performed by a surgeon who is highly skilled in both laparoscopic and thyroid surgery.

TOETVA – Transoral endoscopic thyroidectomy vestibular approach, ATA – American Thyroid Association, TIRADS – Thyroid imaging reporting and data system.

## Acknowledgements

I am very grateful to my professor Zach Koto for the support and nurturing. This case series would not have been possible without his support and faith in me.

## Conflict of interest

The authors declare no conflict of interest.

## Funding source

No funding was required.

## Ethical approval

Prior to commencement of the study, ethical approval was obtained from the following ethical review board: Sefako Makgatho University Research Ethics Committee (Ref: SMUREC/M/2025).

## ORCID

WM Mathe  <https://orcid.org/0009-0007-2955-5375>

MZ Koto  <https://orcid.org/0000-0002-9274-2508>

## REFERENCES

1. Anuwong A. Transoral endoscopic thyroidectomy vestibular approach: A series of the first 60 human cases. *World J Surg.* 2016;40(3):491-7. <https://doi.org/10.1007/s00268-015-3320-1>.
2. Choi Y, Lee JH, Kim YH, et al. Impact of post thyroidectomy scar on the quality of life of thyroid cancer patients. *Ann Dermatol.* 2014;26(6):693-9. <https://doi.org/10.5021/ad.2014.26.6.693>.

3. Rahbari R, Zhang L, Kebebew E. Thyroid cancer gender disparity. *Future Oncol.* 2010;6(11):1771-9. <https://doi.org/10.2217/fon.10.127>.
4. Sarkar S, Banerjee S, Sarkar R, Sikder B. A review on the history of 'thyroid surgery'. *Indian J Surg.* 2016 Feb;78(1):32-6. <https://doi.org/10.1007/s12262-015-1317-5>.
5. Tae K, Ji YB, Song CM, Ryu J. Robotic and endoscopic thyroid surgery: Evolution and advances. *Clin Exp Otorhinolaryngol.* 2019;12(1):1-11. <https://doi.org/10.21053/ceo.2018.00766>.
6. Shaha AR Transoral thyroidectomy: Learning curve. *Arch Endocrinol Metab.* 2021 May-Jun;65(3):255-6. <https://doi.org/10.20945/2359-3997000000382>.
7. Haugen BR, Alexander EK, Bible KC, et al. 2015 American thyroid association management guidelines for adult patients with thyroid nodules and differentiated thyroid cancer: The American Thyroid Association Guidelines Task Force on Thyroid Nodules and Differentiated Thyroid Cancer. *Thyroid.* 2016;26(1):1-133. <https://doi.org/10.1089/thy.2015.0020>.
8. Arora A, Swords C, Garas G, et al. The perception of scar cosmesis following thyroid and parathyroid surgery: A prospective cohort study. *Int J Surg.* 2016;25:38-43. <https://doi.org/10.1016/j.ijssu.2015.11.021>.
9. Alci E, Kim SY, Yun HJ, et al. Evaluation of public's perception of scar cosmesis after thyroidectomy: Results of a survey of Turkish versus South Korean individuals. *Ann Surg Treat Res.* 2023;105(3):119-25. <https://doi.org/10.4174/ast.2023.105.3.119>.
10. De Vries LH, Aykan D, Lodewijk L, et al. Outcomes of minimally invasive thyroid surgery: A systematic review and meta-analysis. *Front Endocrinol (Lausanne).* 2021;12:719397. <https://doi.org/10.3389/fendo.2021.719397>.
11. Sivakumar T, Amizhthu RA. Transoral endoscopic total thyroidectomy vestibular approach: A case series and literature review. *J Minim Access Surg.* 2018;14(2):118-23. [https://doi.org/10.4103/jmas.JMAS\\_3\\_17](https://doi.org/10.4103/jmas.JMAS_3_17).
12. Anuwong A, Sasanakietkul T, Jitpratoom P, et al. Transoral endoscopic thyroidectomy vestibular approach (TOETVA): Indications, techniques and results. *Surg Endosc.* 2018;32(1):456-65. <https://doi.org/10.1007/s00464-017-5705-8>.