

Gastro-colic fistula – a rare iatrogenic complication of Nissen fundoplication

IN Palkowski,  ML Kemp 

George Regional Hospital, South Africa

Corresponding author, email: marnie.kemp@gmail.com

Summary

We present a case of an iatrogenic gastro-colic fistula following a Nissen fundoplication which was complicated by extensive adhesions. While gastro-colic fistulae are not an identified complication of Nissen fundoplication, it is, however, a known rare and late complication primarily associated with surgical interventions involving the stomach.

The mainstay of treatment remains nutritional and electrolyte support followed by surgical resection.

Keywords: gastro-colic fistula, rare iatrogenic complication, Nissen fundoplication

Case report

A 41-year-old female, with no history of comorbidities, initially presented with non-resolving gastritis that was thought to be due to a hiatus hernia. She gives a history of abdominal surgery as a child at three years of age. A gastroscopy was performed which demonstrated severe esophagitis and a para-oesophageal hernia. The latter was confirmed with a barium swallow.

At laparoscopy, a diaphragmatic hernia of the fundus of the stomach was present. There were no findings to suggest obstruction or gangrene and a laparoscopic Nissen fundoplication was performed. Multiple adhesions were encountered at the gastric fundus and distal oesophagus which resulted in iatrogenic injuries to the fundus of the stomach and oesophageal gastric junction. The surgery was subsequently converted to an open procedure. Adhesiolysis was performed and the defect in the diaphragm and iatrogenic injuries were repaired. The patient's recovery was uneventful. Instructions on discharge included a fluid diet for six weeks and a follow-up appointment at two weeks, which she defaulted.

The patient represented two months later with adhesive bowel obstruction that was successfully managed conservatively. She was subsequently discharged after three days stay in hospital.

She represented five months after the initial surgery with symptoms of bowel obstruction and vomiting of feculent fluid. The abdomen was distended but soft and non-tender. There were no systemic signs of sepsis.

An abdominal X-ray demonstrated large and small bowel obstruction. A gastroscopy was performed which identified stool in the stomach, but no fistulous tract was found. A subsequent contrast meal and small bowel follow-through study demonstrated a fistula between the greater curvature of the stomach and the transverse colon (Figure 1).

The patient had a preoperative albumin of 27 grams per decilitre (g/dl) (normal range 35–52 g/dl) and a normal renal function. The rest of the blood results were unremarkable. An exploratory laparotomy demonstrated a gastro-colic fistula

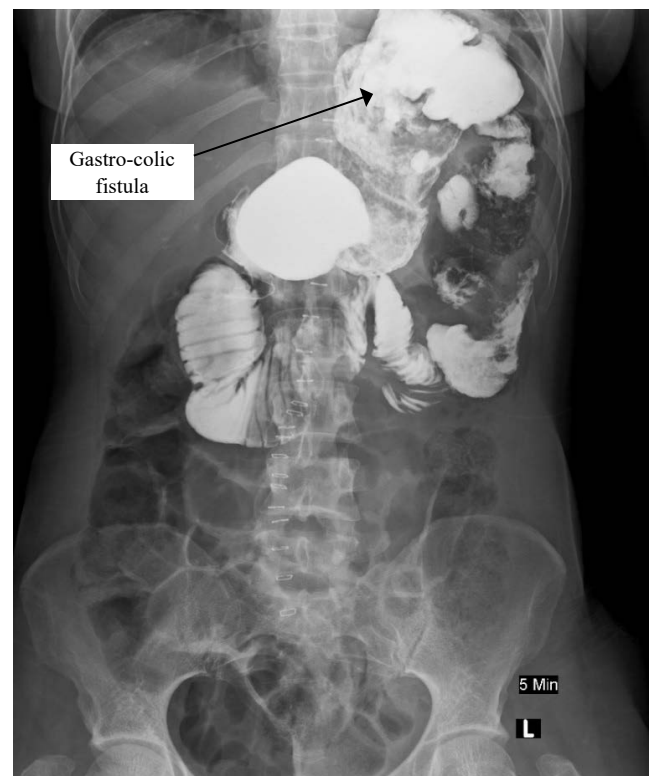


Figure 1: Contrast entering the transverse colon from the stomach at 5 minutes

between the transverse colon and the greater curvature of the stomach. There was a significant burden of adhesions present in the upper abdomen. The colon just distal to the gastro-colic fistula was completely occluded resulting in an over distended and ischemic proximal large bowel.

There was no presence of a tumour or inflammatory bowel disease macroscopically.

Resection of the fistula at the greater curvature of the stomach and an extended right hemi-colectomy was performed. A side-to-side anastomosis was performed

between the terminal ileum and descending colon using vicryl 3/0. The defect in the stomach was repaired with vicryl 3/0.

Histological analysis of the resected fistula showed granulation tissue in keeping with a fistula. Histological analysis of the resected distal colon, with attached stomach, showed inflammation, granulation tissue and scarring.

On the fifth postoperative day, the patient complicated with intra-abdominal sepsis. An abdominal ultrasound proved intra-abdominal collections. She was taken for a relook laparotomy on the same day which demonstrated thin intra-abdominal pus collections and an intact anastomosis. Fluid was taken for microscopy and sensitivity, and the abdominal cavity was washed out. She was transferred to the ward postoperative. On the tenth postoperative day, the patient complicated with septic shock. She was intubated and transferred to the intensive care unit (ICU). An abdominal computerised tomography (CT) scan was performed which showed multiple intra-abdominal collections. The patient was then transferred to a tertiary hospital for CT guided pigtail catheter drainage of the collections and continued ICU care. The patient subsequently recovered and was discharged home. The pigtail catheter was removed after 14 days when the drainage was less than 50 ml. She has been following up regularly and still complains of intermittent vomiting without feculent content but is gaining weight appropriately. A follow-up barium meal demonstrated delayed gastric emptying but no fistulous tract. A gastroscopy and barium enema were also performed that did not identify any fistulous tract.

Discussion

Gastro-colic fistulas are a rare disorder of the gastro-intestinal tract, defined as an abnormal connection between the epithelial surface of the colon and the stomach, respectively.¹ The identified aetiologies encompass several factors, with transverse colon carcinoma emerging as the predominant cause, occurring in 0.3–0.4% of reported cases in the Western population. Other significant aetiologies include gastric carcinoma, inflammatory bowel disease, prior abdominal surgery, benign gastric ulcers, and exposure to radiation.²

While gastro-colic fistulae are not an identified complication of Nissen fundoplication, it is a known rare late complication primarily associated with surgical interventions involving the stomach.³ The most common site of the fistulous tract is between the greater curvature of the stomach and the transverse colon.¹

In this case report, we suspect that the cause of the gastro-colic fistula is likely an iatrogenic thermal injury of the stomach and/or transverse colon that occurred during a difficult dissection to perform the Nissen fundoplication and was not apparent at the time of the surgery.

Presenting complaints include vomiting of feculent material, abdominal pain, diarrhoea and weight-loss.⁴ Patients often present with a diminished nutritional status and electrolyte disturbances due to abnormal diversion of gastric contents and subsequent lack of absorption.⁵

Gastro-colic fistulas can be demonstrated by use of a barium enema with a sensitivity of up to 95–100%. The use of a barium swallow is helpful in diagnosing gastro-colic fistula, but the sensitivity is much lower at under 30%.⁶ The

causative agent in both imaging modalities, however, may not be identified.⁶

An abdominal-pelvic CT scan with oral contrast scan may illustrate the extent of the fistula and its underlying cause.⁶ However, sensitivity and specificity rates are suboptimal.⁶

Gastroscopy and colonoscopy are imperative diagnostic tools aimed at excluding the presence of gastric or colonic malignancies.⁵ These must be used with other imaging modalities as the fistulas can be easily missed during endoscopy as identified in this case report.⁵

Recommended management consists of improving nutritional and electrolyte status preoperatively with the use of total parental nutrition and intravenous fluids. This is followed by a single stage *en bloc* resection of the fistula with involved portions of the stomach and colon.^{1,7,8} In this case report, the patient had complete bowel obstruction that failed conservative management and required definitive urgent surgery. Albumin levels of > 35 g/dl has been shown to reduce postoperative complications and overall mortality rate in patients undergoing major abdominal surgery.⁹

More recently, advanced endoscopic methods have been developed to close benign gastro-colic fistula with varying success rates. These modalities include endoscopic stent placement, endoscopic clipping and endoscopic suturing.¹⁰ The success rate is limited by the size of the fistula. Long-term success rates and efficacy still need to be established.¹⁰

A history of childhood abdominal surgery (excluding uncomplicated appendectomy) should be considered a potential red flag for complex reoperative procedures in adulthood.¹¹ Consulting with colleagues at a tertiary centre may be advisable to identify potential challenges and obtain guidance on optimal patient management.

We would also like to emphasise from this case report that patients who present with recurrent symptoms (in this case, bowel obstruction) without peritonitis or signs of sepsis should be carefully assessed in respect of physiological reserve prior to being subjected to extensive surgery.⁵

Consulting with colleagues at a tertiary centre may once again be advisable for optimal management.

Conflict of interest

The authors declare no conflict of interest.

Funding source

No funding source to be declared.

Ethical approval

Approval granted from research ethics committee. University of Cape Town, Faculty of Health Sciences, Human Research Ethics Committee. HREC REF number 083/2024.

No medical statisticians required as this is a single-patient case report.

There is no patient identifying information. Informed written consent has been obtained.

There is no racio-ethnic-cultural category stated in the study as this is a single-patient case report.

ORCID

IN Palkowski  <https://orcid.org/0000-0001-8641-2265>

ML Kemp  <https://orcid.org/0000-0002-5214-9961>

REFERENCES

1. Stamatakos M, Karaikos I, Pateras I, et al. Gastrocolic fistulae: from Haller till nowadays. *Int J Surg.* 2012;10(3):129-33. <https://doi.org/10.1016/j.ijso.2012.02.011>.
2. Singh V, Wadleigh R. Gastrocolic fistula as a complication of colon carcinoma: a case report. *Acta Oncol.* 1997;36(8):817-8. <https://doi.org/10.3109/02841869709001363>.
3. Wu JM, Wang MY, Lee PH, Lin MT. Gastrojejunal fistula after gastrojejunostomy: a case series. *J Med Case Rep.* 2008;2(1):1-3. <https://doi.org/10.1186/1752-1947-2-193>.
4. Barrett K, Hii MW, Cade RJ. Benign gastro-colic fistula in a woman presenting with weight loss and intermittent vomiting: a case report. *J Med Case Rep.* 2011;5:313. <https://doi.org/10.1186/1752-1947-5-313>.
5. Mansour S, Marjiyeh-Awwad R, Khuri S. Gastrocolic fistula: an extraordinary gastrointestinal fistula. *Gastroenterol Res.* 2022;15(6):308-13. <https://doi.org/10.14740/gr1576>.
6. Thoeny RH, Hodgson JR, Scudamore HH. The roentgenologic diagnosis of gastrocolic and gastrojejunal fistulas. *Am J Roentgenol Radium Ther Nucl Med.* 1960;83:876-81.
7. Aydin U, Yazici P, Ozütemiz O, Güler A. Outcomes in the management of gastrocolic fistulas: a single surgical unit's experience. *Turk J Gastroenterol.* 2008;19(3):152-7.
8. Cody JH, DiVincenti FC, Cowick DR, Mahanes JR. Gastrocolic and gastrojejunal fistulae: Report of twelve cases and review of the literature. *Ann Surg.* 1975;181(3):376-80. <https://doi.org/10.1097/0000658-197503000-00021>.
9. Ahmed J, Sarma NM. Preoperative serum albumin as predictor of adverse outcome in emergency abdominal surgery. *Int Surg J.* 2022;9(5):1034. <https://doi.org/10.18203/2349-2902.isj20221151>.
10. Bhurwal A, Mutneja H, Tawadross A, Pioppo L, Brahmabhatt B. Gastrointestinal fistula endoscopic closure techniques. *Ann Gastroenterol.* 2020;33(6):554-62. <https://doi.org/10.20524/aog.2020.0543>.
11. Das S. Pediatric surgical diseases and legacy of pediatric surgery in adults - responsibility of pediatric surgeons. *J Indian Assoc Pediatr Surg.* 2018;23(4):180. https://doi.org/10.4103/jiaps.JIAPS_131_18.