

# Adult small bowel volvulus – a case series

GL Shelile,<sup>1,2</sup> K Sepeng,<sup>1,3</sup> TCK Gofhamodimo,<sup>1,3</sup> KM Ngoepe,<sup>3</sup> T Mukhuba,<sup>3</sup> K Manyane<sup>4</sup>

<sup>1</sup> Sefako Makgatho Health Science University, South Africa

<sup>2</sup> Dr George Mukhari Academic Hospital, South Africa

<sup>3</sup> Job Shimankana Tabane Hospital, South Africa

<sup>4</sup> Bongani Hospital, South Africa

Corresponding author, email: lefa.shelile@gmail.com

## Summary

Small bowel volvulus (SBV) is a rare cause of bowel obstruction, specifically in adults, accounting for approximately 1% of bowel obstruction in the adult population in North America. It is more common in the neonatal and paediatric population, mostly due to congenital abnormalities such as malrotation, atresia and congenital bands. We present two cases of SBV managed at a level 2 provincial hospital within a 2-month period. In the first case no primary cause could be found and in the second case adhesions following midline laparotomy resulted in SBV.

**Keywords:** small bowel volvulus, bowel obstruction

## Case reports

**Patient 1:** A 36-year-old male presented with a 5-day history of right iliac fossa pain, constipation and abdominal distension. He had no known comorbidities and no history of previous operations. Clinically he was acutely ill with a tachycardia and signs of dehydration, but not pyrexial. Examination of the abdomen revealed gross distention and generalised peritonitis. Blood gas analysis revealed a metabolic acidosis and formal laboratory bloods an acute renal injury (urea of 18.6 mmol/l [reference range 2.1–7.1 mmol/l] and a creatinine of 114 μmol/l [reference range 64–104 μmol/l] as well as an elevated C-reactive protein of 304 mg/l (reference range < 10 mg/l) but a normal white cell count of 6.76 x10<sup>9</sup>/L. Multiple dilated loops of small bowel with air fluid levels were noted on abdominal x-ray. The clinical diagnosis was severe acute appendicitis with a paralytic ileus. The patient was resuscitated with intravenous fluids, and broad-spectrum antibiotics commenced. Once his condition was optimised,

he was taken to theatre for exploration. Laparoscopy was initially attempted as per institutional policy for all patients with a diagnosis of severe appendicitis. This approach was converted to an open procedure due to poor visualisation. A small bowel volvulus (SBV) with ischaemic bowel and an area of necrosis was found at formal laparotomy (Figure 1). Without detorting the mesentery, the affected bowel was resected (approximately 90 cm of the ileum, 10 cm proximal to the ileocecal valve), the ends clipped and dropped into the peritoneal cavity. Temporary abdominal closure was achieved, and the patient was admitted to ICU for supportive care. A planned re-look laparotomy was scheduled in 48 hours. At the second laparotomy a double barrel stoma was fashioned, and the abdomen was closed. His postoperative course was complicated by surgical site infection on the laparotomy wound, which was managed conservatively. He was discharged home with a stoma on postoperative day 25.

**Patient 2:** A 17-year-old male presented with a 3-day history of abdominal pain, vomiting and constipation. A

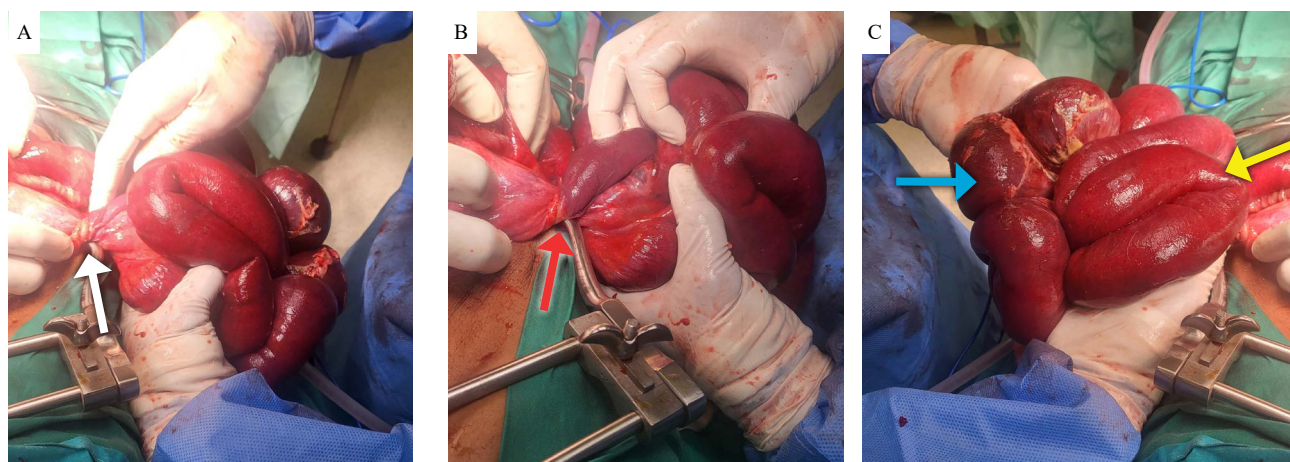


Figure 1: Intraoperative pictures. A: white arrow – twisted small bowel mesentery. B: red arrow – another view of the twist. C: blue arrow – necrotic bowel, yellow arrow – ischaemic bowel

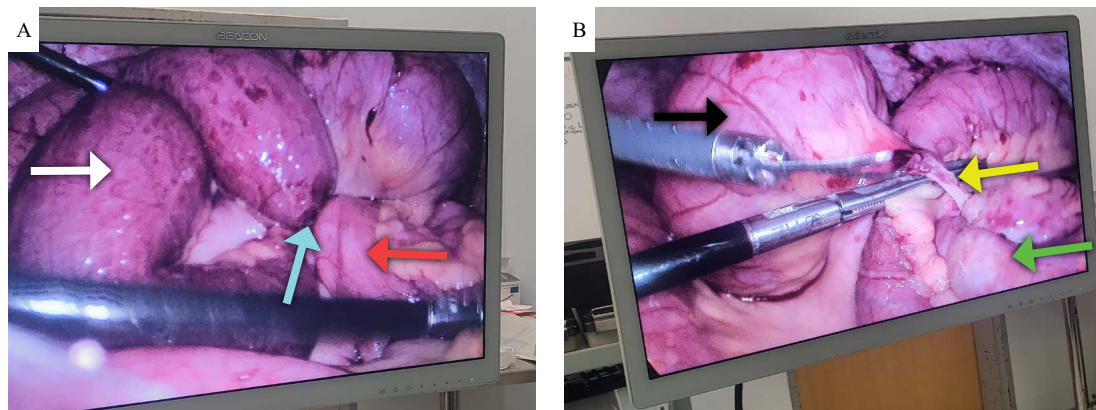


Figure 2: Laparoscopic pictures. A: white arrow – dilated proximal loop of small bowel with some ischaemic features, blue arrow – mesenteric twisting, red arrow – distal collapsed loop of small bowel. B: detorted mesentery with improved colour of the bowel, black arrow – previously ischaemic proximal bowel now with improved colour, yellow arrow – interloop adhesiolysis being performed, green arrow – previously collapsed distal bowel now filling.

laparotomy for complicated appendicitis had been performed 3 months prior to presentation. On examination, he was diaphoretic with abdominal distension and tenderness on palpation, most pronounced on the lower abdomen. His vital signs and blood gas analysis were unremarkable. The C-reactive protein was elevated at 42 mg/l (reference range < 10 mg/l). Abdominal x-rays demonstrated multiple loops of dilated small bowel. Adhesive small bowel obstruction was the primary differential diagnosis based on the history of a previous laparotomy. The degree of tenderness and elevated C-reactive protein precluded a trial of conservative management and, similar to the first patient, this patient was taken to theatre without further imaging. Explorative laparoscopy, using the open Hassen technique for placement of the camera port and direct vision for additional port placement, was performed. At laparoscopy, varying severity of adhesions, including interloop adhesions, were encountered. After blunt and sharp adhesiolysis, small bowel twisted around its mesentery due to an adhesive band was noted in the right upper quadrant. In addition, complex interloop adhesions and a loop of bowel with ischaemic features were noted (Figure 2). The bowel was detorted and immediately regained normal colour. After dividing the adhesive band, the distal collapsed loop immediately filled. His postoperative course was uneventful. Feeds were introduced on day 1 and he was discharged on postoperative day 3 with simple analgesia and an outpatient clinic follow-up appointment.

## Discussion

SBV is rare and more common in the Middle East, Asia and some parts Africa, particularly in the paediatric population.<sup>1,2,3</sup> It is classified as primary, where an underlying cause cannot be identified, and secondary where there is an identifiable cause.<sup>3,4</sup> The pathophysiology is not well understood and postulated to be due to dietary (fibre and serotonin-rich diets, fasting) and anatomical factors (longer mesentery and shorter mesenteric attachments).<sup>4,5,6</sup> Awedew et al. reported a high yearly incidence of approximately 37 cases of SBV per year, and SBV represented 56% of cases of small bowel obstruction in Ethiopia.<sup>7</sup> In contrast Roggo et al. reported 35 cases of SBV over a 10-year period in the USA.<sup>4</sup> Similarly, Huang and colleagues also followed patients for a period of 10 years at a hospital in Taiwan, reporting only 19 cases of

SBV.<sup>6</sup> This supports the notion that geographic location and dietary factors contribute to the incidence of SBV.

Adhesions are the most common cause of secondary SBV in adults. In the era of laparoscopic surgery, this phenomenon may be less common, as it is well documented that the incidence and severity of adhesions is less with laparoscopy.<sup>8</sup>

It is important to have a high index of suspicion when patients present with signs and symptoms of bowel obstruction. If SBV is not recognised early the consequences can be dire, specifically if there is bowel necrosis.<sup>3</sup>

There is paucity of data on SBV in South Africa. Globally, most cases are recorded as case reports and retrospective studies, likely due to the low incidence of SBV. The mortality and morbidity associated with SBV are significant, and it is important for clinicians to have a high index of suspicion of primary SBV in patients with no previous operations or with no known congenital anatomical abnormalities. Early surgical exploration is important in these patients, as the mortality and morbidity are significantly higher if there are delays. The reported mortality rates are estimated to be approximately 9–35% and between 20–100% in the presence of bowel necrosis.<sup>5</sup>

Our 2 cases represent two spectra of the condition, primary SBV with late presentation and secondary SBV with earlier presentation. In both cases the diagnosis was made intraoperatively and both did not have preoperative cross-sectional imaging. The use of cross-sectional imaging and ultrasonography to identify SBV has been described, with the presence of a whirl sign on computerised tomography scan highly suggestive of SBV; however the sensitivity and specificity are low, and these should not delay surgical management.<sup>6,9</sup> We accept that imaging could have offered more information and increased the suspicion of SBV, however, it is questionable whether imaging would have changed the management or the outcomes of our patients. There is not enough evidence to recommend either laparoscopy or open procedure for management of these patients; both are mentioned as reasonable approaches.<sup>10</sup> Laparoscopy is an appropriate surgical option with possibly less morbidity than laparotomy, but this has not been specifically proven for SBV. Ideally, laparoscopy should be performed in well-selected patients, at a centre familiar with the skills and in the presence of a senior surgeon. At our institution, laparoscopy is offered to most patients with

an acute abdomen, provided they are hemodynamically stable with reasonable biochemical parameters. We accept that perhaps the first patient, who ultimately had a damage control procedure, should have been offered laparotomy at the outset, and that laparoscopy added to the theatre time.

More research is still needed on this condition, and it appears African institutions are better positioned to carry it out due to the number of patients seen.

### **Acknowledgement**


We would like to thank Mr Matlou Mabitsela, from Dr Sefako Makgatho health science university general surgery research office, for his assistance with finalising the publication logistics.


### **Ethical approval**


Ethical approval was obtained from the Sefako Makgatho University Research Ethics Committee (Ref No: SMUREC/M/66/2023).


### **ORCID**


GL Shelile  <https://orcid.org/0009-0003-8032-0230>

K Sepeng  <https://orcid.org/0009-0008-3280-6275>

TCK Gofhamodimo  <https://orcid.org/0009-0002-9466-4459>

KM Ngoepe  <https://orcid.org/0009-0006-1085-356X>

T Mukhuba  <https://orcid.org/0009-0007-7314-1444>

K Manyane  <https://orcid.org/0009-0000-6654-0649>

### **REFERENCES**

1. Coe TM, Chang DC, Sicklick JK. Small bowel volvulus in the adult populace of the United States: results from a population-based study. *Am J Surg.* 2015;210(2):201-210.e2. <https://doi.org/10.1016/j.amjsurg.2014.12.048>.
2. Gourishetti S, DeMeo SD. Neonatal segmental small bowel volvulus with normal intestinal rotation. *J Pediatr Surg Case Rep.* 2021;64:101721. <https://doi.org/10.1016/j.epsc.2020.101721>.
3. Gürleyik E, Gürleyik G. Small bowel volvulus: A common cause of mechanical intestinal obstruction in our region. *Eur J Surg.* 2003;164(1):51-5. <https://doi.org/10.1080/110241598750004959>.
4. Roggo A, Ottinger LAW. Acute small bowel volvulus in adults: A sporadic form of strangulating intestinal obstruction. *Ann Surg.* 1992;216(2):135-41. <https://doi.org/10.1097/0000658-199208000-00003>.
5. Barabde M, Tiwari S, Lavankar V. Small bowel volvulus: A rare twist in an adult. *Int J Sci Rep.* 2016;2(2):44. <https://doi.org/10.18203/issn.2454-2156.IntJSciRep20160503>.
6. Huang JC, Shin JS, Huang YT, et al. Small bowel volvulus among adults. *J Gastroenterol Hepatol.* 2005;20(12):1906-12. <https://doi.org/10.1111/j.1440-1746.2005.03945.x>.
7. Awedew AF, Belay WB, Amsalu BT, Yalewu DZ. Small bowel volvulus (SBV) in Northcentral Ethiopia. *BMC Surg.* 2020;20(1):221. <https://doi.org/10.1186/s12893-020-00886-6>.
8. Ten Broek RPG, Krielen P, di Saverio S, et al. Bologna guidelines for diagnosis and management of adhesive small bowel obstruction (ASBO): 2017 update of the evidence-based guidelines from the world society of emergency surgery ASBO working group. *World J Emerg Surg.* 2018;13(1):24. <https://doi.org/10.1186/s13017-018-0185-2>.
9. Gollub MJ, Yoon S, Smith LM, Moskowitz CS. Does the CT whirl sign really predict small bowel volvulus? *J Comput Assist Tomogr.* 2006;30(1):25-32. <https://doi.org/10.1097/01.rct.0000191680.28344.f0>.
10. Tsang CLN, Joseph CT, de Robles MSB, Putnis S. Primary small bowel volvulus: An unusual cause of small bowel obstruction. *Cureus.* 2019;11(12):e6465. <https://doi.org/10.7759/cureus.6465>.