

An ascaris twist

IN Palkowski¹ 

George Regional Hospital, South Africa

Corresponding author, email:

ivan.palkowski@westerncape.gov.za

Summary

A five-year-old male presented with small bowel obstruction and a worm bolus on a plain abdominal radiograph. Peritonism and acidosis prompted laparotomy after a short period of resuscitation. At surgery a worm bolus had caused a small bowel volvulus with a segment of necrosis that was successfully managed by detorsion and resection. This highlights that though ascaris lumbricoides, a common parasite in impoverished communities, has many mild manifestations the most life-threatening complication is volvulus. Hence when worm bolus is suspected vigilant observation to detect sepsis, acidosis and peritonism is essential to expedite surgery and prevent the morbidity of perforation.

Keywords: ascaris, small bowel volvulus, perforation, peritonitis, paediatrics

Case report

A five-year-old male with no comorbidities presented to the emergency department with a two-day history of worsening abdominal pain, anorexia, obstipation, and worm emesis. The mother reported administering over-the-counter deworming medication one day before visiting the emergency centre. The pain described was generalised and constant. There was no history of passage of worm in the stool. The immunisations were up to date. Features of growth restriction were present with weight for age and height for age being below the 90th percentile.

Clinically the patient was dehydrated and tachycardic. The abdomen was distended and there was generalised tenderness with guarding. There were increased bowel sounds on auscultation. On rectal exam, no stool or worms were detected.

An abdominal X-ray demonstrated features of small bowel obstruction with a worm bolus visible within the small bowel (Figure 1). Arterial blood gas analysis revealed a compensated metabolic acidosis (pH 7.37, bicarbonate (HCO₃) 14.8 mmol/l, base excess - 7.8 mmol/l, lactate 1.2 mmol/l and pCO₂ 3.3 Kpa) (normal ranges pH 7.35 - 7.45, HCO₃ 22 - 26 mmol/l, base excess -2 - +2 mmol/l, lactate < 2 mmol/l and pCO₂ 4.7 - 6.0 Kpa respectively). Blood analysis showed a raised white cell count at 20.12 x 10⁹/L (normal values 6.00 - 16.00 x 10⁹/L). Of note, the eosinophil count was normal at 0 x10⁹/l (normal values 0.0 - 0.5 x10⁹/l) and haemoglobin was slightly elevated for his age at 15.4 g/dl (normal values 9.5 - 14 g/dL).

The patient was resuscitated with intravenous fluids over four hours with marked improvement in his hemodynamic status and blood gas analysis. Despite analgesia, his abdominal exam remained unchanged. He was then scheduled for an emergency exploratory laparotomy where a small bowel volvulus with a segment of necrotic bowel and imminent perforation affecting the mid-ileum was noted (Figure 2). Intestinal worms were felt throughout the small bowel and large mesenteric lymph nodes were also present. The bowel was detorted, and the intestinal worms milked

towards the cecum. Approximately 20 cm of ischemic and necrotic small bowel was then resected. An end-to-end anastomosis was performed with a running Vicryl 4/0 suture.

Postoperatively the patient was extubated and transferred to the intensive care unit (ICU) for close observations. Feeds were slowly introduced. On the third postoperative day, the patient passed a worm bolus per rectum. The patient was discharged home on the fifth postoperative day. Mebendazole was administered prior to discharge.

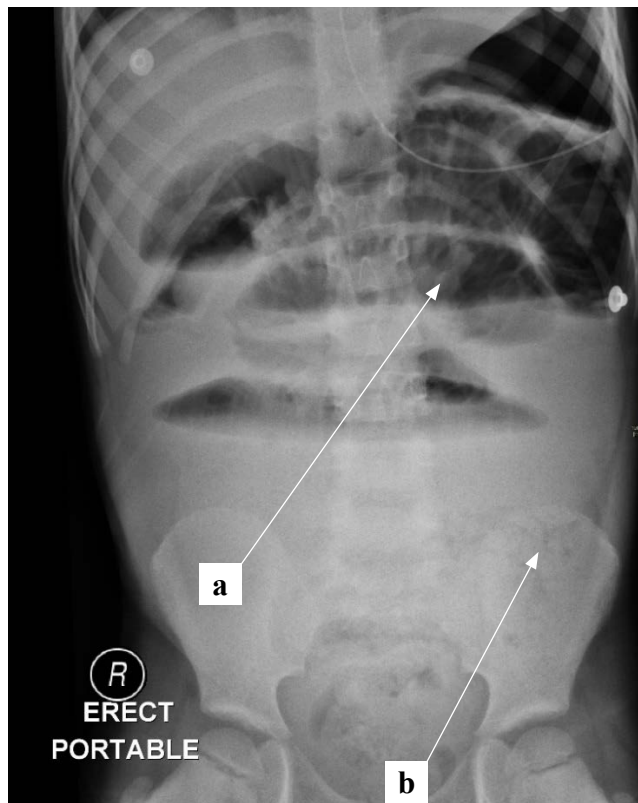


Figure 1: Abdominal X-ray demonstrating small bowel obstruction and an intestinal worm bolus – a) dilated small bowel loops with air-fluid levels, b) intestinal worm bolus

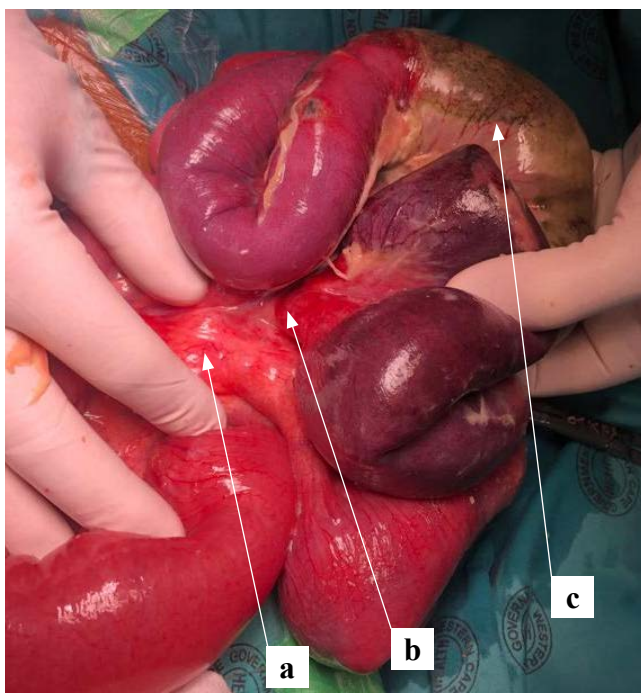


Figure 2: Detorted small bowel volvulus with imminent perforation – a) enlarged mesenteric lymph nodes, b) point of torsion, c) necrotic small bowel with imminent perforation

The patient was followed up at the surgical outpatient department 10 days later and was reported to be doing well.

Histology of the resected small intestine showed transmural necrosis and infarction compatible with an ischaemic aetiology. *Ascaris* infection was present. The mesenteric nodes included in the resection demonstrated reactive lymphoid hyperplasia.

Discussion

Small bowel volvulus, characterised by the twisting of a segment of the small intestine around its mesentery, is a rare yet critical condition in paediatric patients.¹ The rotation of the bowel on its axis can lead to bowel obstruction and compromised blood supply that may lead to ischaemia, infarction, and perforation necessitating prompt recognition and intervention.¹

Small bowel volvulus is an uncommon cause of bowel obstruction in children and infants accounting for less than 8% of all cases of intestinal obstruction in this population.^{2,3}

The overall mortality rate for small bowel volvulus in the paediatric population is 3.1%.⁴

Small bowel volvulus may arise from either primary or secondary factors. Primary volvulus occurs independently of structural abnormalities, whereas secondary small bowel volvulus may result most commonly from adhesions, intestinal strictures, neoplastic lesions, hernias, foreign bodies, intussusception, intestinal worms, or other anatomical abnormalities such as a Meckel's diverticulum, requiring varied treatment approaches based on the underlying pathology.^{4,5} The incidence of small bowel volvulus due to mesenteric lymph nodes alone is, however, extremely rare but has been reported in a case study.⁶

In our case report, the most obvious cause for the volvulus were worms causing a mass effect on the small intestine and resulting in a volvulus. Although the most common site of volvulus due to intestinal worms has been reported to be at

the ileocecal junction,⁵ in our case the volvulus was located in the mid-ileum. Other case reports with small bowel volvulus due to intestinal worms have also noted large mesenteric lymph nodes; these nodes may play a minor contributing factor to the volvulus by acting as a pivot point.⁷

Symptoms of small bowel volvulus are often non-specific ranging from cramp-like diffuse abdominal pain, bilious vomiting, abdominal distention, constipation or diarrhoea and fever.⁸

Diagnostic images for small bowel volvulus include plain abdominal X-rays that may identify small bowel obstruction and an abdominal contrasted tomography (CT) scan. An abdominal CT scan may demonstrate a characteristic whirlpool sign, however the accuracy to identify small bowel volvulus can be as low as 45%.⁸ Intestinal *ascaris* can sometimes be identified on plain abdominal X-rays. A large cluster of worms can be seen, highlighted by intestinal gas, with an irregular border between the worm mass and the surrounding gas shadows. Individual worms may appear as linear or bubble-shaped radiolucency.⁹

Identifying small bowel volvulus poses a diagnostic challenge as no singular symptom, clinical sign, or aberrant laboratory result encompasses both primary and secondary presentations; moreover, reliance on abdominal imaging alone may not consistently yield sufficient diagnostic clarity, potentially leading to life-threatening delays in diagnosis.⁸ Adequate fluid resuscitation and prompt surgical intervention is therefore required to reduce morbidity and mortality.^{5,8,10}

Management options for intestinal volvulus due to intestinal worms depends on the viability and perfusion of the bowel. In most reported cases, there was a high incidence of non-viable bowel requiring resection and anastomosis.^{5,7}

In these case reports of small bowel volvulus due to worms, the volvulus was detorted, and the worms were milked distally and carefully into the cecum prior to resection of non-viable bowel and then anastomosis, similar to our case report.^{5,7}

A 10-year study on small bowel volvulus concluded that manual detorsion without resection is an appropriate management option for non-compromised bowel.¹¹

If a worm bolus is found in the proximal small bowel and causing obstruction, it is advised to remove the worm bolus through an enterotomy by making a longitudinal incision in the small bowel and removing the worms. Milking the worms from the proximal small bowel distally towards the cecum may cause injury to the bowel.⁷

It is worth noting that although this devastating and rare complication can arise from intestinal worms, other intestinal complications can occur when there is a history suggestive of intestinal worms. These include partial or complete bowel obstruction from worm bolus (the most common complication), and other rarer intestinal complications such as intussusception, perforation, and appendicitis.⁵

Abdominal pain in children can be difficult to interpret with a large list of differential diagnoses posing even further challenges. Passage of an intestinal worm accompanied by disproportionate abdominal pain should alert the clinician to potential complications that can arise from intestinal worms, as described in this case report. Recognising the need for early surgical intervention in these cases may decrease overall morbidity and mortality.

Conflict of interest

The authors declare no conflict of interest.


Funding source

No funding was required.

Ethical approval

Ethical approval granted from research ethics committee, University of Cape Town, Faculty of Health Sciences, Human Research Ethics Committee. HREC REF number 082 /2024. No medical statisticians required as this is a single patient case report. There is no patient identifying information. Informed written consent has been obtained. There is no racio-ethnic-cultural category stated in the study as this is a single patient case report.

ORCID

IN Palkowski  <https://orcid.org/0000-0001-8641-2265>

REFERENCES

1. Frazee RC, Mucha P, Farnell MB, Van Heerden JA. Volvulus of the small intestine. *Ann Surg.* 1988;208(5):565-8. <https://doi.org/10.1097/0000658-198811000-00004>.
2. Ooko PB, Wambua P, Oloo M, et al. The spectrum of paediatric intestinal obstruction in Kenya. 2016;24. <https://doi.org/10.11604/pamj.2016.24.43.6256>.
3. Ghritlaharey RK, Budhwani KS, Shrivastava DK. Exploratory laparotomy for acute intestinal conditions in children: A review of 10 years of experience with 334 cases. *Afr J Paediatr Surg.* 2011;8(1):62-9. <https://doi.org/10.4103/0189-6725.78671>.
4. Schwartz DM, Fong ZV, Chang DC. Small bowel volvulus in paediatric patients: A nationwide population-based analysis. *Academic Surgical Congress Abstracts Archive [Internet].* 2016. Available from: <https://www.asc-abstracts.org/abs2016/73-11-small-bowel-volvulus-in-pediatric-patients-a-nationwide-population-based-analysis/>.
5. Ramareddy RS, Alladi A, Siddapa OS, et al. Surgical complications of *Ascaris lumbricoides* in children. *J Indian Assoc Pediatr Surg.* 2012;17(3):116-9. <https://doi.org/10.4103/0971-9261.98130>.
6. Qayyum A, Cowling MG, Adam EJ. Small bowel volvulus related to a calcified mesenteric lymph node: case reports. *Clin Radiol.* 2000;55(6):483-5. <https://doi.org/10.1053/crad.2000.0092>.
7. Molla YD, Beza AD, Tadesse AK, Answar IO. *Ascaris lumbricoides* a rare cause ileal perforation, a case report. *Int J Surg Case Rep.* 2023;105. <https://doi.org/10.1016/j.ijscr.2023.108097>.
8. Boume MA, Adabra K, Amavi AKA, et al. Idiopathic small bowel volvulus in children: Report of two cases. *J Pediatr Surg Case Reports.* 2017;23:18-20. <https://doi.org/10.1016/j.epsc.2017.05.018>.
9. Hartung M, Radswiki T. Ascariasis. *Radiopaedia.* 2010. <https://doi.org/10.53347/rID-11406>.
10. Kawatra V, Arora P, Lakshmikantha A, Varma D, Khurana N. Gangrene intestine caused by *Ascaris lumbricoides*: report of 5 cases in children. *Pathol Res Pract.* 2010;206(5):292-4. <https://doi.org/10.1016/j.prp.2009.10.003>.
11. Roggo A, Ottinger LW. Acute small bowel volvulus in adults. A sporadic form of strangulating intestinal obstruction. *Ann Surg.* 1992;216(2):135-41. <https://doi.org/10.1097/0000658-199208000-00003>.