

# Inflammatory myofibroblastic tumours of the liver – a systematic review

M Li,<sup>1,2,3</sup> S Sobnach,<sup>1</sup> UK Kotze,<sup>1</sup> LF Zerhini,<sup>3</sup> JM Millis,<sup>4</sup> DA Hampton,<sup>4</sup> MM Bernon,<sup>1</sup> JEJ Krige,<sup>1</sup> EG Jonas<sup>1</sup>

<sup>1</sup> Division of General Surgery, Department of Surgery, Groote Schuur Hospital, University of Cape Town, South Africa

<sup>2</sup> University of Chicago Centre for Global Health, United States of America

<sup>3</sup> Cancer Genomics Group, International Centre for Genetic Engineering and Biotechnology, University of Cape Town, South Africa

<sup>4</sup> Department of Surgery, University of Chicago Medicine, United States of America

Corresponding author, email: sanjusobnach@yahoo.com

**Background:** Hepatic inflammatory myofibroblastic tumours (HIMTs) are rare and poorly described in the literature. Most publications are single patient case reports and lack detailed reporting on characteristics, management, and outcomes. This systematic review aimed to assess the demography, clinical presentation, typical imaging features, histopathology, treatment, and outcomes of patients presenting with HIMTs.

**Methods:** A systematic literature search was performed in MEDLINE (PubMed), EMBASE (Scopus), JSTOR, Cochrane CENTRAL (Cochrane Library), and the databases included in the Web of Science for studies published between 1940 and 2023 on HIMTs, including its reported synonyms. Case series or cohort studies that reported on the management and outcomes of at least four patients with histologically confirmed HIMTs were included in the analysis.

**Results:** After screening 4553 publications, 22 articles including a total of 440 patients with confirmed HIMTs were eligible for inclusion. The average age was 53.4 years (range 42.0–65.0) with a male to female ratio of 1.7:1. Abdominal pain, discomfort, fever, and loss of weight were the most common presenting symptoms. Surgical resection is the standard of care for HIMTs and is associated with low mortality of 3.4% and low disease recurrence.

**Conclusion:** HIMT is a disease more often affecting middle-aged males. The lesions are typically solitary with low recurrence after treatment. The relative roles of surgical versus medical treatment remain unclear. Differences in clinical presentation, histopathology, and treatment of HIMTs compared to inflammatory myofibroblastic tumour (IMT) at extrahepatic sites could challenge the current view of IMT as a single pathological entity.

**Keywords:** inflammatory myofibroblastic tumours, inflammatory pseudotumours, liver, hepatic, treatment outcome, systematic review

## Introduction

Inflammatory myofibroblastic tumour (IMT) is an uncommon condition characterised by the proliferation of myofibroblastic spindle cells with concomitant inflammatory cell infiltration.<sup>1,2</sup> Although IMT is the recommended terminology for the condition, other terms such as inflammatory pseudotumour, inflammatory fibrosarcoma, plasma cell granuloma, post-inflammatory tumour, xanthomatous pseudotumour, and sclerosing pseudotumour have been used interchangeably in the medical literature.<sup>3</sup> Inflammatory myofibroblastic tumours tend to occur in the lungs where they typically have an indolent course. They may also occur in the genitourinary tract (bladder, uterus), gastrointestinal tract (liver, stomach, spleen), and upper respiratory tract (larynx, trachea) where a risk of malignant transformation exists.<sup>3</sup>

Hepatic inflammatory myofibroblastic tumours (HIMTs) are rare. Although the aetiology of HIMTs remains unknown, it has been postulated that the presence of bacterial organisms within these tumours and their response to antibiotic therapy support an infectious aetiology. Several bacteria and viruses have been identified in these lesions, including Epstein-Barr virus, actinomyces, parasitic fragments, gram-positive

cocci, *Klebsiella pneumoniae*, and *Escherichia coli*.<sup>4-10</sup> It has been hypothesised that HIMTs represent an organising form of liver abscess (LA) secondary to blood borne infection or ascending cholangitis. A possible association with cholangiocarcinoma for which cholangitis is a risk factor supports this hypothesis. Obliterating phlebitis has been observed, which suggests ascending infection via the portal venous system.<sup>11-13</sup> The right-sided predominance, multiplicity of hepatic lesions, and the findings of synchronous inflammatory tumours in the spleen and lungs support the presence of a circulating agent, which would favour an infective course.<sup>14-16</sup>

Histologically, these lesions show inflammation and fibrosis in varying proportions. Neutrophils, lymphocytes, and plasma cells predominate the inflammatory cell infiltrates with frequently observed bacterial organisms.<sup>17</sup> HIMTs can mimic malignant tumours and are often radiologically and pathologically misdiagnosed as hepatocellular carcinoma (HCC), LA, haemangioma, intrahepatic cholangiocarcinoma (IHCC), liver metastases, or focal nodular hyperplasia. Treatment includes antibiotics and surgical resection. We performed a systematic review to assess the demography, clinical presentation, typical

imaging features, histopathology, treatment and treatment outcomes of patients with HIMTs.

## Material and methods

The systematic review was conducted following the Preferred Reporting Items for Systematic Reviews and Meta-Analyses (PRISMA) guidelines.<sup>18</sup> The study protocol was registered in the International Prospective Register of Systematic Reviews (PROSPERO) (registration no: CRD42023434670) on the 25<sup>th</sup> of June 2023.

### Search strategy

A systematic search of the published literature from 1 January 1940 to 1 June 2023 was performed with no language restriction. MEDLINE (PubMed), EMBASE (Scopus), JSTOR, Cochrane CENTRAL (Cochrane Library), and the databases included in the Web of Science were searched using a search strategy that was drafted with the assistance of a university librarian. The full list of our search strategy is provided in the supplementary information (Supplementary Table I).

### Study selection

All duplicates were removed prior to screening. Titles and abstracts of all articles were independently screened by two authors [ML, SS]. Additional studies were identified from the review of references in the included articles. The full texts of articles were retrieved and independently reviewed by [ML, SS] for eligibility. The selection was restricted to the following criteria case series or cohort studies that included: at least four patients with histopathological confirmation of HIMTs, adults 18 years and older, and that reported the management and outcome of patients. For institutions with multiple publications, the most recent paper was included to prevent double reporting. Any disagreement was resolved through discussions between the two reviewers until a consensus was reached. A third reviewer (EJ) assisted in cases of further disagreement. There were no language exclusions in this systematic review.

### Risk of bias and quality assessment

The Newcastle-Ottawa Scale was applied to assess the risk of bias and quality of cohort studies and comparative studies. A tool proposed by Murad et al. was used for the included case series with an absence of non-exposed cohort or comparability between cohorts.<sup>19,20</sup> Two reviewers (ML, SS) worked independently to calculate the quality from the included studies. Any disagreements were resolved in consultation with the senior author (EJ).

### Data extraction

A specifically designed Microsoft Excel spreadsheet was used to collect all relevant data. Extracted variables included study characteristics (first author, year of publication, country of origin, number of patients included), patient demographics (gender and age), clinical presentation, blood tests (hepatitis B virus (HBV) status and white blood cell (WBC) count), imaging features (imaging modalities used, tumour imaging features, and number of lesions), histopathological characteristics, treatment (definitive medical treatment and surgery), and outcomes (morbidity

and mortality). Postoperative complications were graded according to the Clavien-Dindo classification.<sup>21</sup>

### Statistical analysis

Continuous variables were reported as means with standard deviation (SD) or medians with range, while categorical variables were presented as frequencies and percentages.

## Results

The results of the systematic literature search are shown in Figures 1 and 2. A total of 4553 publications were identified in the database search and another three from citation searches. After duplicates and single patient case reports were excluded, 1138 records were screened, of which 82 full-text articles were reviewed. Twenty-two papers were included in the final review of which 15 studies were of high quality, five were of medium quality, and the remaining two were of low quality (Supplementary Table IV). Twenty papers were case series with more than four cases reported, and the remaining two papers included one cohort study and one comparative study.<sup>24,25</sup> Three of the papers<sup>23,26,29</sup> were in Chinese and one in French<sup>8</sup> as the authors were collectively fluent in these two languages.

The included articles yielded a total of 440 patients. Study characteristics, patient demographics, and clinical presentations are summarised in Figure 1 and detailed in supplementary Table II. The majority of the studies originated from Asian countries (China, South Korea, Japan, and India; 17 studies, 388 patients), and the remaining 52 patients were from Brazil, New Zealand, the UK, and the US (five studies). The number of studies originating per country is shown in Supplementary Figure 1. The number of patients included in the studies ranged from four to 114. Of the 440 patients assessed, 279 (63.4%) were male and 161 (36.6%) were female. The gender distribution was 1.8:1 (253 males:139 females) for patients in the Asian publication group compared to 1.2:1 (26 males:22 females) in patients from the non-Asian publication group.

In the papers that expressed age as a mean, the average was 53.6 years (range 42.0–65.0). In one publication in which the median was used, it was reported as 49.5 years. The most common symptoms at presentation were abdominal pain and/or discomfort (261 patients, 59.3%), fever (188 patients, 42.7%), loss of weight (48 patients, 10.9%), malaise (39 patients, 8.9%), and nausea or vomiting (36 patients, 8.2%). Jaundice at presentation was unusual (17 patients, 3.9%), and 53 patients (12.0%) were asymptomatic. In 14 studies HBV status was reported. Of the 332 tested patients, 72 were positive (21.7%). In 15 studies the WBC count was reported. Of the 199 tested patients, 58 were reported to have leucocytosis (29.1%). In nine articles, tumour markers were normal. In eight articles, raised tumour marker values were noted. Serum alpha-fetoprotein (AFP) levels were reported in 49 patients, of whom four (8.2%) had elevated values (range 98.8–1080.0 ng/mL); carbohydrate antigen (CA19-9) was reported in 80 patients, of whom 12 (15%) had elevated values (range 45.42 U/mL–842.0 U/mL).

As far as cross-sectional imaging is concerned, computed tomography (CT) was the most frequently used cross sectional imaging modality (263 patients, 59.8%), followed by ultrasonography (US) (260 patients, 59.1%) and magnetic resonance imaging (MRI) (140 patients, 31.8%) (Supplementary Table III). A total of 371 (84.3%)

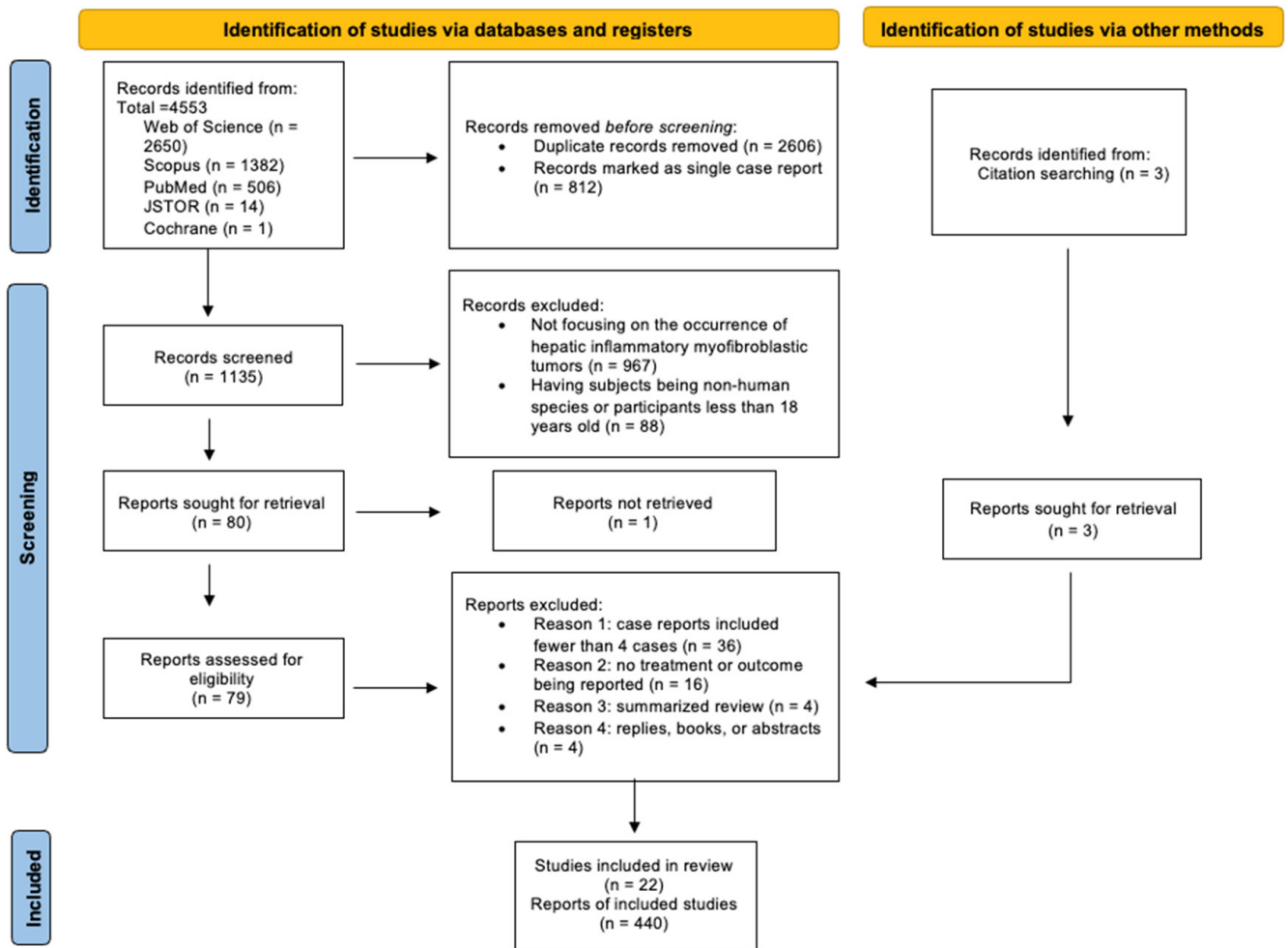


Figure 1: PRISMA flow diagram of the studies selection in database search and other methods.

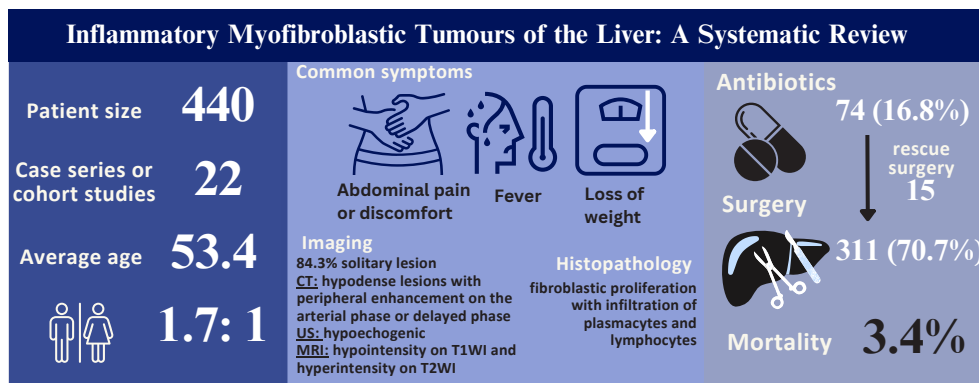


Figure 2

and 69 patients (15.7%) had solitary and multiple lesions respectively. Lesions were mostly assessed as hypoechoic on US. The most common tumour specific CT findings were poorly defined hypodense lesions on the pre-contrasted stage with peripheral enhancement on the arterial phase or delayed phase. Two attributes were consistently described on MRI, namely hypointensity on T1-weighted images (T1WI) and hyperintensity on T2-weighted images (T2WI). The use of FDG-PET/CT was described in ten patients; all had FDG avid lesions. Twenty-four (5.5%) patients were reported as having underlying liver cirrhosis.

Biopsies were performed in 152 (34.5%) patients of whom 34 had inconclusive results. The typical microscopic

appearance of biopsy samples was fibroblastic proliferation with infiltration of plasmacytes, lymphocytes, eosinophils, histiocytes, and neutrophils. Clusters of xanthomatous cells and collagen fibres with ovoid nuclei were also reported. Nine studies commented on the immunohistochemistry. IgG4 positivity was reported in 12 patients, whereas smooth muscle actin (SMA) and vimentin positivity were reported in 103 patients and 94 patients respectively. Nineteen articles interrogated pre-treatment misdiagnoses that were reported in 198 patients (45%). In 193 (97.5%) patients, the final diagnosis was different from the imaging diagnosis – the type of suspicion of an unclassified malignancy (71), HCC (32), LA (31), unspecified metastatic cancer (24), IHCC (7)

**Table I: Treatment and outcomes of HIMTs**

First author, year	Treatment		Postoperative morbidity (n)	Mortality n (%)
	Antibiotics / Rescue surgery (n)	Surgical (n)		
Calomeni, 2013 <sup>17</sup>	3/3	4	Grade II (1) Grade IVa (1)	2 (50) 1 on the 10 <sup>th</sup> day; 1 on the 23 <sup>rd</sup> day
Li, 1989 <sup>22</sup>	NR	4	NR	0 (0)
Qiu, 2013 <sup>23</sup>	1/0	8	Grade IVa (4)	4 (44.4)*
Yang, 2014 <sup>24</sup>	9/9	10	NR	0 (0)
Tang, 2010 <sup>25</sup>	NR	64	Grade I (3) Grade II (1) Grade IIIa (6) Grade IVa (1)	0 (0)
Yang, 2015 <sup>11</sup>	NR	114	Grade I (22) Grade II (20) Grade IIIa (25) Grade IVa (1)	0 (0)
Gao, 2023 <sup>26</sup>	NR	7	NR	0 (0)
Tsou, 2006 <sup>27</sup>	2/0	4	NR	1 (12.5)*
Xiao, 2013 <sup>28</sup>	NR	7	NR	0 (0)
Liang, 2014 <sup>29</sup>	NR	15	NR	0 (0)
Nigam, 2019 <sup>30</sup>	11/0	6	NR	2 (11.8) 1 at 2 months; 1 unknown
Ijuin, 1997 <sup>31</sup>	6/0	1	NR	0 (0)
Horiuchi, 1990 <sup>32</sup>	2/1	7	Grade I (1) Grade II (1)	2 (25) 1 at 18 months; 1 unknown
Yoon, 1999 <sup>12</sup>	NR	10	NR	1 (10)
Kang, 2013 <sup>33</sup>	NR	2	NR	0 (0)
Ahn, 2011 <sup>34</sup>	6/0	22	Grade IVa (1)	2 (9.1) 1 in-hospital; 1 at 18 months
Park, 2014 <sup>35</sup>	15/0	10	NR	0 (0)
Oh, 2021 <sup>13</sup>	NR	8	NR	0 (0)
Koea, 2003 <sup>36</sup>	1/0	—	NR	1 (20) one at 3 months
Milias, 2009 <sup>37</sup>	2/2	4	Grade II (1) Grade IIIa (1)	0 (0)
Stoll, 2010 <sup>38</sup>	NR	3	NR	0 (0)
Arora, 2021 <sup>39</sup>	16/0	4	NR	0 (0)

— Not conducted or patient received observational treatment only.

NR – Not reported,

\* Time of death not specified

Postoperative complications are graded with the Clavien-Dindo classification<sup>21</sup>

– (Supplementary Table V). In five (2.5%) patients, there was discordance between the preoperative biopsy and final histology.

Treatment modalities and their corresponding outcomes are summarised in Table I. A total of 74 (16.8%) patients received antibiotics, of whom 15 subsequently underwent surgery. Three hundred and eleven patients (70.7%) underwent liver resection. An effort was made to harmonise the terminology used in the different papers with the Brisbane 2000 system to determine the proportions of major (3 segments) versus minor (< 3 segments) resections.<sup>40</sup> Due to the use of non-descriptive and non-standardised terminology, this was not possible although one series reported a distribution of 62 minor versus two major resections.<sup>25</sup>

Postoperative major complications were reported in only seven of the articles and were graded as Clavien-Dindo grade I in

26 (5.9%) patients, grade II in 24 (5.5%), grade IIIa in 32 (7.2%) patients, and grade IVa in seven (1.6%) patients.

Only two articles reported a total of three postoperative mortalities.<sup>17,34</sup> Long-term survival was inconsistently reported, and no statistical analysis was possible. Interestingly, in the study conducted by Qiu et al., the four (50%) deaths were due to cerebral hemorrhage.<sup>23</sup> Surgical resection was reported to have low recurrence rates (8%).

## Discussion

HIMT is a rare condition that was first described by Pack and Baker in 1953 as granulomatous lesions with dense bundles of interlacing fibroblasts.<sup>41</sup> A total of four organ-specific systematic reviews have been performed on non-hepatic IMTs, including urinary bladder, sinonasal and

ventral skull base, nasopharynx, and lower cranial nerve.<sup>42-45</sup> To the best of our knowledge, this systematic review focusing on HIMTs is the first of its kind in the literature. Comparisons between HIMTs and IMTs from extrahepatic sites showed some interesting similarities and differences in terms of demography, clinical presentation, histopathology, and treatment (Supplementary Table VI).

The male to female ratio of 1.7:1 of HIMTs in our review is similar to the ratios that were observed for patients with IMTs in the skull base, nasopharynx, and gastrointestinal tract.<sup>43,44,47</sup> A larger male to female ratio was observed in patients with IMTs in the lower cranial nerve and limbs.<sup>45,49</sup> Female predominance was seen in patients with IMTs in the urinary bladder and jaw bones.<sup>42,48</sup> The age of patients with different disease sites seemed to be similar. In the groups where the mean age was lower, some paediatric patients were included, which was an exclusion criterium for our study. Abdominal pain and/or discomfort, fever, loss of weight or anorexia, malaise, and nausea or vomiting were the most common symptoms in HIMT patients in our review. Although pain and fever were prominent symptoms in some of the presentations, symptom complexes seemed to be dominated by symptoms specific to the organs involved.

HIMTs were mostly solitary with only 15% of patients having been reported as having multiple lesions. In the publications describing extrahepatic IMTs, lesion multiplicity was commented in 56 patients of whom only three (5.4%) had multiple lesions. In HIMT patients, 29.1% had elevated WBC counts, but in the papers on extrahepatic IMTs, only one paper mentioned leucocytosis in four of 38 (10.5%) patients.<sup>47</sup>

On histology, fibroblastic spindle cell proliferation with infiltration of predominantly plasma cells and lymphocytes were reported in all IMTs irrespective of involved organs. On immunohistochemistry, ALK expression and/or ALK gene rearrangement positivity were mentioned by Stoll and Li as a feature for HIMT patients.<sup>38</sup> In non-hepatic IMTs, ALK was expressed in the urinary bladder and uterus.<sup>42,46</sup> Smooth muscle actin (SMA) and vimentin stains were more often positive in HIMTs and were also reported in the urinary bladder, uterus, gastrointestinal tract, jaw bones, and limbs.<sup>42,46-49</sup> Although positive immunostainings and elevated WBC count correlate with proliferation of inflammatory cells and can be considered as an indicator of HIMTs, it is not sufficient for IMT diagnosis and should be reviewed with clinical and microscopic findings. Tumour markers, including AFP, CA 19-9 and CEA, were unhelpful. The relative high prevalence of chronic HBV infection in studies where it was reported (21.7%), should be interpreted with caution. This was higher than the reported prevalence of chronic HBV in the general population in China (6.89%) from where most of the patients in the systematic review were reported.<sup>50</sup> This, however, cannot be interpreted as causality. Patients with chronic HBV infection are at higher risk of hepatic malignancies, which in a substantial number of patients was the indication for surgery.

In most studies in our systematic review, significant proportions of patients were treated successfully with antibiotics. Interestingly, the most commonly used medication for conservative management of non-hepatic IMTs was steroids, which was not reported for the treatment of HIMTs in any of the assessed publications.<sup>43-45,48</sup> In the reviewed articles, 70.7% of patients with HIMTs underwent

surgery, compared to 50.2% of extrahepatic IMT patients. The indication for surgery in patients with HIMTs was malignancy in 134 (43.1%) of the resected patients.

We acknowledge that this systematic review has several limitations. First, the quality of data that was generally poor, incomplete, and inconsistent reporting precluded further quantitative studies. Second, regarding the quality evaluation, one of the criteria proposed by Murad et al. was based on the dose-response effect for non-surgical treatment, which was not applicable to surgical reporting.<sup>20</sup> The systematic review was therefore purely descriptive. Moreover, due to the selective and incomplete reporting, the low mortality (3.4%) in our review is very likely an underestimation.

## Conclusion

This systematic review shows HIMT is a disease of middle-aged males. The aetiology remains obscure. The lesions are typically solitary with low recurrence after treatment. With a significant proportion of resections for HIMTs being performed on suspicion of malignancy, the relative roles of surgical versus medical treatment remain unclear.

Despite some similarities, differences in clinical presentation, histopathology, and treatment of HIMTs compared to IMTs at extrahepatic sites could challenge the current understanding of IMT as a single pathological entity which should probably be revisited.

## Conflict of interest

The authors declare no conflict of interest.

## Funding source

This research did not receive any funding.


## Ethical approval

Not required. Word count 2373 words

Presented by Mingyang Li in Poster form at the Consortium of Universities for Global Health, 7–10 March 2024, Westin Bonaventure, Los Angeles, California.

## ORCID

M Li  <https://orcid.org/0009-0009-8259-0887>


S Sobnach  <https://orcid.org/0000-0002-4456-2115>

UK Kotze  <https://orcid.org/0000-0003-1405-474X>

LF Zerbin  <https://orcid.org/0000-0003-0736-9508>

JM Millis  <https://orcid.org/0000-0002-5361-5776>

DA Hampton  <https://orcid.org/0000-0002-9870-0835>

MM Bernon  <https://orcid.org/0000-0002-7967-8548>

JEJ Krige  <https://orcid.org/0000-0002-7057-9156>

EG Jonas  <https://orcid.org/0000-0003-0123-256X>

## REFERENCES

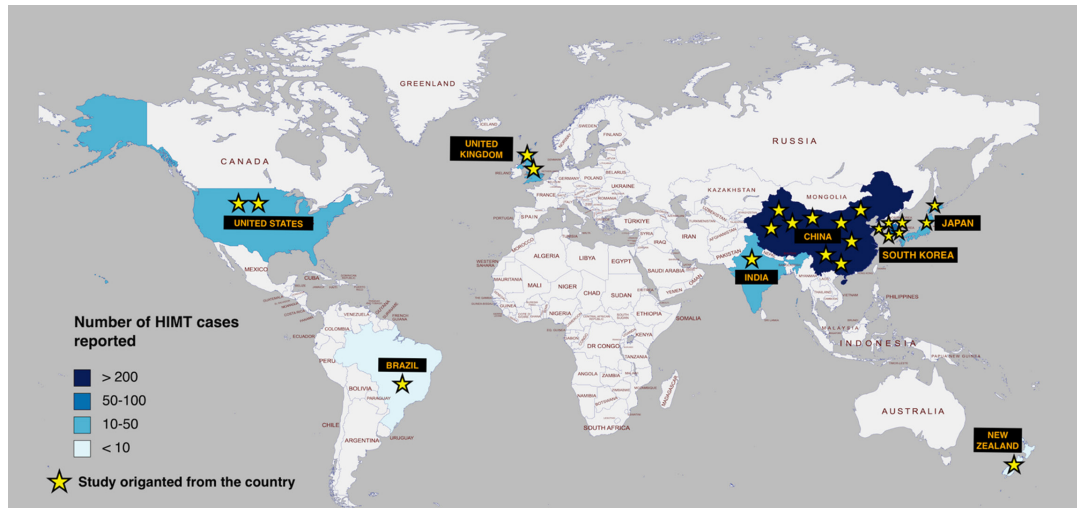
1. Tay SY, Balakrishnan A. Laryngeal inflammatory myofibroblastic tumour (IMT): A case report and review of the literature. *J Med Case Rep.* 2016;10:180. <https://doi.org/10.1186/s13256-016-0967-7>.
2. Masuda Y, Kanazawa Y, Goto O, et al. Primary gastric inflammatory myofibroblastic tumour treated with non-exposed endoscopic wall-inversion surgery (news): A case report and literature review. *DEN Open.* 2023;4:e243. <https://doi.org/10.1002/deo2.243>.
3. Siemion K, Reszec-Gielazyn J, Kisluk J, et al. What do we know about inflammatory myofibroblastic tumours? A

- systematic review. *Adv Med Sci.* 2022;67:129-38. <https://doi.org/10.1016/j.advms.2022.02.002>.
4. Arber DA, Weiss LM, Chang KL. Detection of Epstein-Barr virus in inflammatory pseudotumour. *Semin Diagn Pathol.* 1998;15:155-60.
  5. Standiford SB, Sobel H, Dasmahapatra KS. Inflammatory pseudotumour of the liver. *J Surg Oncol.* 1989;40:283-7. <https://doi.org/10.1002/jso.2930400416>.
  6. Tambay R, Côté J, Bourgault A-M, et al. An unusual case of hepatic abscess. *Can J Gastroenterol.* 2001;15:615-7. <https://doi.org/10.1155/2001/897154>.
  7. Lupovitch A, Chen R, Mishra S. Inflammatory pseudotumour of the liver. Report of the fine needle aspiration cytologic findings in a case initially misdiagnosed as malignant. *Acta Cytol.* 1989;33:259-62.
  8. Le Borgne J, Lehur PA, Bitar O, et al. Les pseudo-tumeurs inflammatoires du foie. *Chirurgie.* 1991;117:840-7.
  9. Malatjalian DK, Morris J, Bodurtha A. Isolation of klebsiella pneumoniae from a hepatic inflammatory pseudotumour. *Can J Gastroenterol.* 1992;6:84-6. <https://doi.org/10.1155/1992/594034>.
  10. Kafel G, Telesinghe PU. Inflammatory pseudotumour of the liver. *J Clin Pathol.* 1997;50:352-3. <https://doi.org/10.1136/jcp.50.4.352>.
  11. Yang X, Zhu J, Biskup E, et al. Inflammatory pseudotumours of the liver: Experience of 114 cases. *Tumour Biology.* 2015;36:5143-8. <https://doi.org/10.1007/s13277-015-3167-y>.
  12. Yoon K-H, Ha HK, Lee JS, et al. Inflammatory pseudotumour of the liver in patients with recurrent pyogenic cholangitis: CT-histopathologic correlation. *Radiology.* 1999;211:373-9. <https://doi.org/10.1148/radiology.211.2.r99ma36373>.
  13. Oh K, Hwang S, Ahn C-S, et al. Clinicopathological features and post-resection outcomes of inflammatory pseudotumour of the liver. *Ann Hepatobiliary Pancreat Surg.* 2021;25:34-8. <https://doi.org/10.14701/ahbps.2021.25.1.34>.
  14. Anthony PP, Telesinghe PU. Inflammatory pseudotumour of the liver. *J Clin Pathol.* 1986;39:761-8. <https://doi.org/10.1136/jcp.39.7.761>.
  15. Anthony PP. Inflammatory pseudotumour (plasma cell granuloma) of lung, liver and other organs. *Histopathology.* 1993;23:501-3. <https://doi.org/10.1111/j.1365-2559.1993.tb00508.x>.
  16. Shek TW, Ng IO, Chan KW. Inflammatory pseudotumour of the liver. Report of four cases and review of the literature. *Am J Surg Pathol.* 1993;17:231-8. <https://doi.org/10.1097/0000478-199303000-00003>.
  17. Calomeni GD, Ataide EB, Machado RR, et al. Hepatic inflammatory pseudotumour: A case series. *Int J Surg Case Rep.* 2013;4:308-11. <https://doi.org/10.1016/j.ijscr.2013.01.002>.
  18. Moher D, Liberati A, Tetzlaff J, et al. PRISMA Group. Preferred reporting items for systematic reviews and meta-analyses: The PRISMA statement. *BMJ.* 2009;339:b2535. <https://doi.org/10.1136/bmj.b2535>.
  19. Wells GA, Shea B, O'Connell D, et al. The Newcastle-Ottawa Scale (NOS) for assessing the quality of nonrandomised studies in meta-analyses. *Appl Eng Agric.* 2014;18(6):727-34.
  20. Murad MH, Sultan S, Haffar S, Bazerbachi F. Methodological quality and synthesis of case series and case reports. *BMJ Evid Based Med.* 2018;23:60-63. <https://doi.org/10.1136/bmjebm-2017-110853>.
  21. Clavien PA, Barkun J, de Oliveira ML, et al. The Clavien-Dindo classification of surgical complications. *Ann Surg.* 2009;250:187-96. <https://doi.org/10.1097/SLA.0b013e3181b13ca2>.
  22. Li G-H, Li J-Q, Lin Y-Z. Inflammatory pseudotumour of the liver. *J Surg Oncol.* 1989;42:244-8. <https://doi.org/10.1002/jso.2930420409>.
  23. Qiu Y-F, Du Q-W, Yang W-L. The cause, diagnosis and treatment of hepatic inflammatory pseudotumour: A report of 9 cases. *Hans J Surg.* 2013;2:32-4. <https://doi.org/10.12677/HJS.2013.24008>.
  24. Yang X, Miao R, Yang H, et al. Retrospective and comparative study of inflammatory myofibroblastic tumour of the liver. *J Gastroenterol Hepatol.* 2015;30:885-90. <https://doi.org/10.1111/jgh.12846>.
  25. Tang L, Lai EC, Cong W, et al. Inflammatory myofibroblastic tumour of the liver: A cohort study. *World J Surg.* 2009;34:309-13. <https://doi.org/10.1007/s00268-009-0330-x>.
  26. Gao Y, Yu P, Cao L. Clinical characteristics and treatment strategies of hepatic inflammatory myofibroblastic tumour. *Journal of Hepatopancreatobiliary Surgery.* 2023;35: 219-24.
  27. Tsou Y-K, Lin C-J, Liu N-J, et al. Inflammatory pseudotumour of the liver - report of eight cases, including three unusual cases, and a literature review. *J Gastroenterol Hepatol.* 2007;22:2143-7. <https://doi.org/10.1111/j.1440-1746.2006.04514.x>.
  28. Xiao Y, Zhou S, Ma C, et al. Radiological and histopathological features of hepatic inflammatory myofibroblastic tumour: Analysis of 10 cases. *Clin Radiol.* 2013;68:1114-20. <https://doi.org/10.1016/j.crad.2013.05.097>.
  29. Liang Y-R, Huang S-H, Bao S-Y, et al. Hepatic inflammatory myofibroblastic tumours: Analysis of 24 cases. *World Chinese Journal of Digestology.* 2014;22:2952. <https://doi.org/10.11569/wcj.d.v22.i20.2952>.
  30. Nigam N, Rajani SS, Rastogi A, et al. Inflammatory pseudotumours of the liver: Importance of a multimodal approach with the insistence of needle biopsy. *J Lab Physicians.* 2019;11:361-8. [https://doi.org/10.4103/JLP.JLP\\_63\\_19](https://doi.org/10.4103/JLP.JLP_63_19).
  31. Ijuin H, Ono N, Koga K, et al. Inflammatory pseudotumor of the liver: MR imaging findings. *Kurume Med J.* 1997;44:305-13. <https://doi.org/10.2739/kurumemedj.44.305>.
  32. Horiuchi R, Uchida T, Kojima T, et al. Inflammatory pseudotumour of the liver. Clinicopathologic study and review of the literature. *Cancer.* 1990;65:1583-90. [https://doi.org/10.1002/1097-0142\(19900401\)65:7<1583::AID-CNCR2820650722>3.0.CO;2-L](https://doi.org/10.1002/1097-0142(19900401)65:7<1583::AID-CNCR2820650722>3.0.CO;2-L).
  33. Kang TW, Kim SH, Jang KM, et al. Inflammatory myofibroblastic tumours of the liver: gadaxetic acid-enhanced and diffusion-weighted MRI findings with 18F-FDG PET/CT and clinical significance of regression on follow-up. *Clin Radiol.* 2014;69:509-18. <https://doi.org/10.1016/j.crad.2013.12.018>.
  34. Ahn KS, Kang KJ, Kim YH, et al. Inflammatory pseudotumours mimicking intrahepatic cholangiocarcinoma of the liver: Igg4-positivity and its clinical significance. *J Hepatobiliary Pancreat Sci.* 2011;19:405-12. <https://doi.org/10.1007/s00534-011-0436-z>.
  35. Park JY, Choi MS, Lim Y-S, et al. Clinical features, image findings, and prognosis of inflammatory pseudotumour of the liver: A multicentre experience of 45 cases. *Gut Liver.* 2014;8:58-63. <https://doi.org/10.5009/gnl.2014.8.1.58>.
  36. Koea JB, Broadhurst GW, Rodgers MS, et al. Inflammatory pseudotumour of the liver: Demographics, diagnosis, and the case for nonoperative management. *J Am Coll*

- Surg. 2003;196:226-35. [https://doi.org/10.1016/S1072-7515\(02\)01495-3](https://doi.org/10.1016/S1072-7515(02)01495-3).
37. Miliias K, Madhavan KK, Bellamy C, et al. Inflammatory pseudotumours of the liver: Experience of a specialist surgical unit. *J Gastroenterol Hepatol.* 2009;24:1562-6. <https://doi.org/10.1111/j.1440-1746.2009.05951.x>.
  38. Stoll LM, Li QK. Cytology of fine-needle aspiration of inflammatory myofibroblastic tumour. *Diagn Cytopathol.* 2010;39:663-72. <https://doi.org/10.1002/dc.21444>.
  39. AroraKS, AndersonMA, NeyazA, et al. Fibrohistiocytic variant of Hepatic Pseudotumour. *Am J Surg Pathol.* 2021;45:1314-23. <https://doi.org/10.1097/PAS.0000000000001767>.
  40. Strasberg SM. Nomenclature of hepatic anatomy and resections: A review of the Brisbane 2000 system. *J Hepatobiliary Pancreat Surg.* 2005;12:351-5. <https://doi.org/10.1007/s00534-005-0999-7>.
  41. Pack GT, Baker HW. Total right hepatic lobectomy. *Ann Surg.* 1953;138:253-8. <https://doi.org/10.1097/00000658-195308000-00012>.
  42. Teoh JY, Chan NH, Cheung HY, et al. Inflammatory myofibroblastic tumours of the urinary bladder: A systematic review. *Urology.* 2014;84:503-8. <https://doi.org/10.1016/j.urology.2014.05.039>.
  43. Desai SV, Spinazzi EF, Fang CH, et al. Sinonasal and ventral skull base inflammatory pseudotumour: A systematic review. *Laryngoscope.* 2015;125:813-21. <https://doi.org/10.1002/lary.24993>.
  44. Mishra S, Suh CH, Bergmark RW, et al. Imaging features, therapies, and outcomes of fibrosing inflammatory pseudotumour of the nasopharynx: A systematic review. *J Neuroimaging.* 2022;32:223-9. <https://doi.org/10.1111/jon.12953>.
  45. Huang SH, Chuang CC, Huang CC, et al. Diagnosis and treatment of inflammatory pseudotumour with lower cranial nerve neuropathy by endoscopic endonasal approach: A systematic review. *Diagnostics.* 2022;12:2145. <https://doi.org/10.3390/diagnostics12092145>.
  46. Mandato VD, Valli R, Mastrofilippo V, et al. Uterine inflammatory myofibroblastic tumour more common than expected: Case report and review. *Medicine.* 2017;96:e8974. <https://doi.org/10.1097/MD.00000000000008974>.
  47. Makhlof HR, Sobin LH. Inflammatory myofibroblastic tumours (inflammatory pseudotumours) of the gastrointestinal tract: How closely are they related to inflammatory fibroid polyps? *Hum Pathol.* 2002;33:307-15. <https://doi.org/10.1053/hupa.2002.32213>.
  48. Neronov A, Livoff A, Nahlieli O, et al. Central inflammatory myofibroblastic tumour of the jawbones: Exceptional location of an uncommon entity. *Arch Clin Med Case Rep.* 2020;4:384-408. <https://doi.org/10.26502/acmcr.96550210>.
  49. Masciocchi C, Lanni G, Conti L, et al. Soft-tissue inflammatory myofibroblastic tumours (IMTs) of the limbs: Potential and limits of diagnostic imaging. *Skeletal Radiol.* 2012;41:643-9. <https://doi.org/10.1007/s00256-011-1263-7>.
  50. Wang H, Men P, Xiao Y, et al. Hepatitis B infection in the general population of China: A systematic review and meta-analysis. *BMC Infect Dis.* 2019;19:811. <https://doi.org/10.1186/s12879-019-4428-y>.

# Inflammatory myofibroblastic tumours of the liver – a systematic review

## Supplementary files



Supplementary Figure 1: Country distribution of the included studies  
 (Created on: <https://www.mapchart.net/world.html>.)

Supplementary Table I: Advanced search strategy for PubMed (Medline) and other databases

#	Field	Search Term
#1	MeSH Terms	liver*
#2	Title/Abstract	inflammatory myofibroblastic tumour
#3	Title/Abstract	inflammatory pseudotumour
#4	MeSH Terms	granuloma, plasma cell
#5	Title/Abstract	inflammatory fibrosarcoma
#6	Title/Abstract	post-inflammatory tumour
#7	Title/Abstract	xanthomatous pseudotumour
#8	Title/Abstract	sclerosing pseudotumour
#9		#2 OR #3 OR #4 OR #5 OR #6 OR #7 OR #8
#10		#1 AND #9
#11	Filter	humans
#12		#10 AND #11

\*The strategy was modified to obtain optimal searching results in different database search engines.

Supplementary Table II: Study characteristics and patient baseline clinical presentations and biochemical results

First author, year	Country of origin	Patients (n)	Gender of patients	Age	Clinical presentations (n)	Biochemical results		
						Hepatitis B+	Leukocytosis	Tumour marker elevation
Calomeni, 2013 <sup>17</sup>	Brazil	4	Male: 3 Female: 1	54.3 ± 18.7*	Abdominal pain / discomfort (3) Fever (2) Hepatomegaly (1) Haemobilia (1) Jaundice (1) Weight loss (1)	0 (0)	1 (25)	NR
Li, 1989 <sup>22</sup>	China	4	Male: 3 Female: 1	42.0 ± 13.0*	Abdominal pain / discomfort (4) Fever (1)	NR	1 (25)	AFP: 1 (25) 1080 ng/mL
Qiu, 2013 <sup>23</sup>	China	9	Male: 7 Female: 2	49.5 (41–65)**	Abdominal pain / discomfort (8) Weight loss / anorexia (4) Fever (2)	1 (11.1)	2 (22.2)	AFP: 1 (11.1)
Yang, 2014 <sup>24</sup>	China	11	Male: 7 Female: 4	45.8 ± 14.4*	Fever / Chills (8) Abdominal pain / discomfort (4) Nausea-Vomiting (1) Back pain (1) Asymptomatic (2)	2 (18.2)	3 (27.3)	AFP: 1 (9.1) 98.78 ng/mL
Tang, 2010 <sup>25</sup>	China	64	Male: 42 Female: 22	49.1 ± 12.5*	Abdominal pain / discomfort (40) Fever (26) Malaise (13) Jaundice (4) Weight loss (2) Asymptomatic (10)	25 (39.1)	NR	NR
Yang, 2015 <sup>11</sup>	China	114	Male: 69 Female: 45	53.1 ± 11.0*	Abdominal pain / discomfort (94) Fever (48) Nausea / vomiting (29) Weight loss (12) Malaise (10)	18 (15.8)	NR	NR
Gao, 2023 <sup>26</sup>	China	15	Male: 11 Female: 4	51.1 ± 8.7*	Abdominal pain / discomfort (5) Fever (3) Asymptomatic (7)	3 (20)	2 (13.3)	CA 19-9: 1 (6.7) 84.9 U/mL
Tsou, 2006 <sup>27</sup>	China	8	Male: 4 Female: 4	59.5 ± 15.2*	Abdominal pain / discomfort (5) Fever (3) Jaundice (3) Weight loss (3) Malaise (1)	1 (12.5)	5 (62.5)	CA 19-9: 3 (75) 79.7 U/mL, 117.92 U/mL, 842 U/mL
Xiao, 2013 <sup>28</sup>	China	9	Male: 4 Female: 5	50.7 ± 11.0*	Abdominal pain / discomfort (7) Fever (6) Weight loss (4) Jaundice (2) Asymptomatic (1)	0 (0)	NR	NR

Supplementary Table II: Continued

First author, year	Country of origin	Patients (n)	Gender of patients	Age	Clinical presentations (n)	Biochemical results n (%)		
						Hepatitis B+	Leukocytosis	Tumour marker elevation
Liang, 2014 <sup>29</sup>	China	24	Male: 21 Female: 3	47.8 ± 15.4*	Fever (16) Abdominal pain / discomfort (4) Asymptomatic (6)	11 (45.8)	1 (4.2)	CA 19-9: 2 (8.3) 62.39 U/mL, 101.73 U/mL
Nigam, 2019 <sup>30</sup>	India	17	Male: 11 Female: 6	47.2 ± 11.2*	Fever (10) Weight loss / anorexia (9) Abdominal pain / discomfort (8) Nausea / vomiting (5) Jaundice (4)	NR	8 (47)	CA 19-9: 2 (13.3) 518.8 U/mL, 147.4 U/mL
Ijuin, 1997 <sup>31</sup>	Japan	8	Male: 2 Female: 6	57.9 ± 10.4*	Fever (5) Weight loss (1) Malaise (1)	1 (12.5)	NR	NR
Horiuchi, 1990 <sup>32</sup>	Japan	8	Male: 7 Female: 1	51.0 ± 18.1*	Fever (6) Abdominal pain / discomfort (5) Weight loss (1) Diarrhea (2) Jaundice (2)	NR	7 (87.5)	NR
Yoon, 1999 <sup>12</sup>	Korea	10	Male: 5 Female: 5	52.2 ± 10.1*	Fever (8) Abdominal pain / discomfort (7) Indigestion (4) Weight loss (1)	NR	3 (30)	NR
Kang, 2013 <sup>33</sup>	Korea	13	Male: 10 Female: 3	55.8 ± 10.6*	Fever (3) Abdominal pain / discomfort (1) Asymptomatic (9)	NR	2 (15.4)	AFP: 1 (8.3) 5630.3 ng/mL
Ahn, 2011 <sup>34</sup>	Korea	22	Male: 16 Female: 6	59.4 ± 9.9*	Abdominal pain / discomfort (12) Fever (5) Malaise (1) Asymptomatic (4)	1 (4.5)	6 (27.3)	AFP: 1 (4.5) 106.5 ng/mL CA19-9: 4 (18.2) 45.42 U/mL, 67.85 U/mL, 76.43 U/mL, 360.5 U/mL
Park, 2014 <sup>35</sup>	Korea	45	Male: 26 Female: 19	65.0 (29-84)***	Abdominal pain / discomfort (16) Fever (11) Malaise (5) Weight loss (4) Asymptomatic (9)	4 (8.9)	10 (22.2)	AFP: 1 (2.2) CEA: 1 (2.2) CA 19-9: 1 (2.2)
Oh, 2021 <sup>13</sup>	Korea	7	Male: 5 Female: 2	62.3 ± 11.6*	Abdominal pain / discomfort (16) Fever (11) Malaise (5) Weight loss (4)	4 (57.1)	NR	NR

Supplementary Table II: Continued

First author, year	Country of origin	Patients (n)	Gender of patients	Age	Clinical presentations (n)	Biochemical results n (%)		
						Hepatitis B+	Leukocytosis	Tumour marker elevation
Koea, 2003 <sup>36</sup>	New Zealand	5	Male: 4 Female: 1	45.8 ± 22.8*	Fever (3) Abdominal pain / discomfort (2) Weight loss (2) Malaise (1) Indigestion (1) Asymptomatic (1)	1 (20)	3 (60)	NR
Miliias, 2009 <sup>37</sup>	UK	4	Male: 2 Female: 2	53.3 ± 16.9*	Abdominal pain / discomfort (4) Fever (2) Malaise (2) Nausea / vomiting (1) Jaundice (1) Pruritus (1)	NR	4 (100)	NR
Stoll, 2010 <sup>38</sup>	US	9	Male: 6 Female: 3	65.3 ± 14.1*	Abdominal pain / discomfort (2) Shortness of breath (1) Fever (1) Asymptomatic (4)	NR	NR	NR
Arora, 2021 <sup>39</sup>	US & UK	30	Male: 14 Female: 16	56.8 ± 16.0*	Abdominal pain / discomfort (14) Fever (8)	NR	NR	NR

NR – Not reported,

\* Mean age (±SD), \*\* Median age (range),

\*\*\* Mean age (range)

Supplementary Table III: Imaging features and histopathological characteristics

First author, year	Imaging features				Histopathological characteristics		
	Solitary / Multiple (n)	CT n (%)	US n (%)	MRI n (%)	Liver biopsy n (%)	Immunohistochemistry (IHC) (n)	Microscopic appearance
Calomeni, 2013 <sup>17</sup>	Solitary (4)	4 (100)	2 (50)	NR	NR	NR	Fibroblastic proliferation with infiltration of plasma cells, lymphocytes, and histiocytes
Li, 1989 <sup>22</sup>	Solitary (4)	4 (100)	4 (100)	NR	NR	NR	Infiltration of plasma cells, histiocytes, and fibroblasts.
Qiu, 2013 <sup>23</sup>	Solitary (9)	9 (100) Precontrast: Irregular, hypodense lesions with poorly defined margins Contrast: Marginal enhancement on the delayed phase Mild enhancement on the arterial phase	9 (100) Hypoechogetic	2 (22.2) Hypointense on T1WI Isointense or hyperintense on T2WI	1 (11.1)	NR	NR
Yang, 2014 <sup>24</sup>	Solitary (8) Multiple (3)	7 (63.6) Precontrast: Hypodense lesions Contrast: Peripheral enhancement on the delayed phase	10 (90.9) Hypoechogetic solid mass	Heterogeneous, mild isointense, or hypointense on T1WI Hypointense center with hyperintense rim on T2WI	1 (9.1)	SMA+ (9) Vimentin+ (3) CD68+ (2) IgG4+ (1)	Fibroblastic proliferation with infiltration of plasma cells, lymphocytes, and/or eosinophils
Tang, 2010 <sup>25</sup>	Solitary (50) Multiple (14)	44 (68.8) Contrast: Peripheral or heterogeneous enhancement	64 (100)	31 (48.4) Hypointense on T1WI Hyperintense on T2WI Heterogeneous or peripheral enhancement on Gadolinium-enhanced images	NR	Vimentin+ (64) SMA+ (57) Desmin+ (41) CD68+ (38)	Fibroblastic proliferation with infiltration of inflammatory cells OR with myxoid, vascular, and inflammatory areas
Yang, 2015 <sup>11</sup>	Solitary (110) Multiple (4)	40 (35.1) Precontrast: Hypodense lesions with well-defined margins. Contrast: Inhomogeneous enhancement on the arterial phase	107 (93.9) Mixed echogenicity	46 (40.3) Hypointense on T1WI Isointense on T2WI	NR	NR	Inflammatory cells with infiltration of predominantly plasma cells and eosinophil
Gao, 2023 <sup>26</sup>	Solitary (11) Multiple (4)	3 (20) FDG-PET/ CT: FDG avid	NR	NR	8 (53.3)	Vimentin+ (11) SMA+ (11) CD68+ (4) CD3+ (4)	Fibroblastic proliferation with infiltration of lymphocytes and plasma cells

Supplementary Table III: Continued

First author, year	Imaging features			Histopathological characteristics			
	Solitary / Multiple (n)	CT n (%)	US n (%)	MRI n (%)	Liver biopsy n (%)	Immunohistochemistry (IHC) (n)	Microscopic appearance
Tsou, 2006 <sup>27</sup>	Solitary (6) Multiple (2)	7 (87.5) Contrasted: Enhancement on the arterial phase Progressive peripheral enhancement on the portal venous and delayed phase	8 (100) Hypoechoic	2 (25)	6 (75)	NR	Aggregation of neutrophils
		9 (100) Precontrasted: Homogeneous lesions with well-defined margins Contrasted: Mild, irregular peripheral enhancement on the arterial phase Heterogeneous enhancement on the portal venous phase Enhancement on the delayed phase Necrosis accompanying haemorrhage	NR	3 (33.3) Inhomogeneous hypointense on T1WI Inhomogeneous hyperintense on T2WI	2 (22.2)	Vimentin+ SMA+ CD 68+ most cases	Fibroblastic proliferation with infiltration of lymphocytes, plasma cells, and eosinophils Ovoid, medium-sized tumour nuclei with smooth nuclear membranes
Xiao, 2013 <sup>28</sup>	Solitary (7) Multiple (2)	20 (83.3) Precontrasted: Hypodense lesions Contrasted: Ring enhancement on the portal venous and delayed phases OR No obvious enhancement	24 (100) Hypoechoic	6 (25) Hypointense on T1WI Inhomogeneous hyperintense on T2WI	9 (37.5)	Vimentin+ (8) SMA+ (8)	Fibroblastic proliferation with infiltration of various inflammatory cells and histiocytes
		15 (88.2) Precontrasted: Hypodense lesions Contrasted: Peripheral rim enhancement on the arterial phase	17 (100) Hypoechoic	6 (35.3) Hypointense on T1WI Hyperintense on T2WI	13 (76.5)	NR	Spindle cells in a dense collagenous background with infiltration of plasma cells and eosinophils Clusters of xanthomatous cells with epithelioid cell granular, multinucleated giant cells
Ijuin, 1997 <sup>31</sup>	Solitary (8)	NR	NR	8 (100) Hypointense on T1WI Hyperintense on T2WI	7 (87.5)	Vimentin+ (8) SMA+ (8) IgG4+ (2)	Collagen fibers in replacement of exfoliated liver cells with infiltration of plasma cells
Horiuchi, 1990 <sup>32</sup>	Solitary (7) Multiple (1)	8 (100) Precontrasted: Irregular or lobulated hypodense lesions	8 (100) Mixed echogenicity	NR	2 (25)	NR	Hyalinized collagenosis in bundles or whorls with infiltration of inflammatory cells Xanthogranuloma with proliferation of foamy histiocytes

Supplementary Table III: Continued

First author, year	Imaging features				Histopathological characteristics		
	Solitary / Multiple (n)	CT n (%)	US n (%)	MRI n (%)	Liver biopsy n (%)	Immunohistochemistry (IHC) (n)	Microscopic appearance
Yoon, 1999 <sup>12</sup>	Solitary (8) Multiple (2)	10 (100) Precontrast: Poorly defined hypodense lesions Contrast: Multiseptate appearance with hyperdense internal septa and periphery	NR	NR	NR	NR	Fibroblastic proliferation with infiltration of foamy histiocytes, plasma cells, and lymphocytes
Kang, 2013 <sup>33</sup>	Solitary (7) Multiple (6)	6 (46.2) FDG-PET/ CT: FDG avid with necrosis	NR	13 (100) Target-like hyper-vascular mass Hypointense, hyperintense, or isointense on T1WI Central hyperintense on T2WI with diffusion restriction	11 (84.6)	NR	Fibroblastic proliferation with infiltration of lymphocytes and plasma cells
Ahn, 2011 <sup>34</sup>	Solitary (17) Multiple (5)	22 (100) Precontrast: Poorly defined hypodense lesions Contrast: Periphery enhancement on the delayed phase	NR	NR	16 (72.7)	IgG4+ (4)	Fibroblastic proliferation with infiltration of histiocytes, lymphocytes, multinucleated giant cells, and neutrophils
Park, 2014 <sup>35</sup>	Solitary (38) Multiple (7)	45 (100) Precontrast: Poorly defined hypodense lesions Contrast: Peripheral enhancement on the arterial phase Hypodense lesions with internal hypodense area on equilibrium phase	NR	23 (51.1) Hypointense on T1WI Homogenous hyperintense on T2WI Peripheral rim enhancement at arterial phase on Gadolinium-enhanced images	36 (80)	NR	Infiltration of plasma cells, lymphocytes, neutrophils, and eosinophils
Oh, 2021 <sup>13</sup>	Solitary (6) Multiple (1)	7 (100)	NR	NR	2 (28.6)	NR	NR
Koca, 2003 <sup>36</sup>	Solitary (3) Multiple (2)	5 (100) Precontrast: Hypodense lesions with poorly defined margins	4 (80)	NR	4 (80)	NR	Fibroblastic proliferation with infiltration of eosinophils and neutrophils
Milias, 2009 <sup>37</sup>	Solitary (4)	4 (100)	3 (75) Cystic lesion	NR	4 (100)	NR	Densely collagenous bundles traverse with infiltration of plasma cells
Stoll, 2010 <sup>38</sup>	Solitary (9)	NR	NR	NR	9 (100)	SMA+ (9) ALK+ (8)	Fibroblastic proliferation with infiltration of inflammatory cells Uniform and bland tumour cells with plump, ovoid or bipolar nuclei and vesicular chromatin
Arora, 2021 <sup>39</sup>	Solitary (19) Multiple (11)	Precontrast: Poorly defined or lobulated hypodense lesions FDG-PET/ CT [1 (3.3)]: FDG avid	Hypoechogetic	Heterogeneously enhancing mass Hyperintense on T2WI	26 (86.7)	IgG4+ (5)	Infiltration of lymphocytes and plasma cells Storiform type fibrosis Atypia in the spindle cell component

NR – Not reported,  
T1WI – Unenhanced T1-weighted images,  
T2WI – T2-weighted images,  
SMA – Smooth muscle actin

**Supplementary Table IV: Risk of bias and quality evaluation of the included studies assessed by the Newcastle-Ottawa Scale or scale proposed by Murad et al.**

Author, year	First Risk of bias
Calomeni, 2013 <sup>17</sup>	High quality 6*
Li, 1989 <sup>22</sup>	Low quality 3*
Qiu, 2013 <sup>23</sup>	Medium quality 6*
Yang, 2014 <sup>24</sup>	High quality 9**
Tang, 2010 <sup>25</sup>	Medium quality 6**
Yang, 2015 <sup>11</sup>	High quality 7*
Gao, 2023 <sup>26</sup>	Medium quality 5*
Tsou, 2006 <sup>27</sup>	High quality 7*
Xiao, 2013 <sup>28</sup>	High quality 6*
Liang, 2014 <sup>29</sup>	High quality 6*
Nigam, 2019 <sup>30</sup>	High quality 6*
Ijuin, 1997 <sup>31</sup>	High quality 6*
Horiuchi, 1990 <sup>32</sup>	High quality 7*
Yoon, 1999 <sup>12</sup>	High quality 6*
Kang, 2013 <sup>33</sup>	High quality 7*
Ahn, 2011 <sup>34</sup>	High quality 7*
Park, 2014 <sup>35</sup>	High quality 7*
Oh, 2021 <sup>13</sup>	Medium quality 5*
Koea, 2003 <sup>36</sup>	High quality 6*
Milias, 2009 <sup>37</sup>	Medium quality 5*
Stoll, 2010 <sup>38</sup>	Low quality 4*
Arora, 2021 <sup>39</sup>	High quality 6*

\* Case series, \*\* Cohort or comparative studies  
Studies scoring between 6-10 were considered 'high quality', scores between 4 and 6 were of 'moderate quality', and scores < 4 were deemed 'low quality'.

**Supplementary Table V: Pre-treatment misdiagnosis reported in the included studies**

First author, year	Misdiagnosis (n)
Calomeni, 2013 <sup>17</sup>	Hepatocellular carcinoma (1) Lymphoproliferative disease and abscess (1) Metastatic cancer (1)
Li, 1989 <sup>22</sup>	Hepatocellular carcinoma (4)
Qiu, 2013 <sup>23</sup>	Misdiagnosis (8)
Yang, 2014 <sup>24</sup>	NR
Tang, 2010 <sup>25</sup>	Unclassified suspicion of malignancy (39)
Yang, 2015 <sup>11</sup>	NR
Gao, 2023 <sup>26</sup>	Liver cancer (4) Other benign disease (4) Intrahepatic cholangiocarcinoma (1) Metastatic cancer (1) Liver abscess (1) Postoperative recurrence of liver cancer (1)
Tsou, 2006 <sup>27</sup>	Hepatocellular carcinoma (3)* Liver abscess (2) Metastatic cancer (1)
Xiao, 2013 <sup>28</sup>	Haemangioma (2) Focal nodular hyperplasia (2) Intrahepatic cholangiocarcinoma (2)
Liang, 2014 <sup>29</sup>	Hepatocellular carcinoma (10) Metastatic cancer (7) Liver abscess (3) Intrahepatic cholangiocarcinoma (2)
Nigam, 2019 <sup>30</sup>	Hepatocellular carcinoma (7) Infectious etiologies (4) Metastatic cancer (2) Intrahepatic cholangiocarcinoma (2) Granulomas (2) Lymphoma (1) Focal nodular hyperplasia (1) Liver abscess (1) Portal cavernoma (1)
Ijuin, 1997 <sup>31</sup>	Suspected hepatocellular carcinoma (1)
Horiuchi, 1990 <sup>32</sup>	Hepatocellular carcinoma (6)
Yoon, 1999 <sup>12</sup>	NR
Kang, 2013 <sup>33</sup>	Liver abscess (1)
Ahn, 2011 <sup>34</sup>	Unclassified suspicion of malignancy (6) Liver abscess (4)
Park, 2014 <sup>35</sup>	Intrahepatic cholangiocarcinoma or hepatocellular carcinoma (23) Liver abscess (8) Lymphoma (2) Liver abscess versus malignancy (1)
Oh, 2021 <sup>13</sup>	The majority of liver masses were diagnosed with hepatocellular carcinoma
Koea, 2003 <sup>36</sup>	Unclassified suspicion of malignancy (2)*
Milias, 2009 <sup>37</sup>	Liver abscess (2) Intrahepatic cholangiocarcinoma (2)
Stoll, 2010 <sup>38</sup>	Metastatic cancer (1)
Arora, 2021 <sup>39</sup>	Metastatic cancer (11) Liver abscess (7)

NR – Not reported, \* Misdiagnosis not resulted from the imaging diagnosis

Supplementary Table VI: Summary of features of IMT on extrahepatic sites

First author, year	Location	Patients(n)	Gender of patients (n) (male:female)	Mean age (± SD)	Clinical presentation (n)	Histological features	Immunohistochemical features (n)	Treatment	
								Medical / Rescue surgery (n)	Surgical (n)
Teoh, 2014 <sup>42</sup>	Urinary bladder	182	Male: 88 Female: 94 1:1.1	38.9 ± 16.6 <sup>p</sup>	Hematuria (69) Dysuria (19) Urinary frequency (18) Lower abdominal pain (13) Loin pain (2)	Spindle cell proliferation with infiltration of plasma cells, lymphocytes, eosinophils, and neutrophils Presence of pleomorphism and necrosis	SMA+: 82 ALK+: 78 Vimentin+: 58 Desmin+: 55	NR	119
Desai, 2014 <sup>43</sup>	Skull base	87	Male: 53 Female: 34 1.6:1	46.7 (4–81) <sup>*p</sup>	Headache (39) Diplopia (29) Vision loss (22) Facial pain (20) Ptosis (17) Proptosis (12) Hearing loss (11) Facial numbness (11) Otagia (9)	Fibrosis with infiltration of lymphocytes and plasma cells	IgG4+: 11	Steroids 68/6 Antibiotics 1/1 Antibiotics and steroids 3/2	20
Mishra, 2021 <sup>44</sup>	Nasopharynx	36	Male: 22 Female: 14 1.6:1	52.2 ± 15.1	Facial pain or headache (36) Cranial nerve (CN) palsies (21) Facial numbness (10)	NR	NR	Steroids 28/0 Antibiotics and steroids 5/1	1
Huang, 2022 <sup>45</sup>	Lower cranial nerve	11	Male: 8 Female: 3 2.7:1	51.3 ± 13.0	Dysphagia (7) Hoarseness (5) Tongue atrophy (5) Abdominal/pelvic pain / discomfort (15)	Fibrosis with infiltration of inflammatory cells	NR	Steroids 5/4	4
Mandato, 2017 <sup>46</sup>	Uterus	72	Male: 0 Female: 72 0:72	40.6 ± 14.9 <sup>p</sup>	Vaginal bleeding (13) Fever/weight loss (5) Urinary disorders (2) Fatigue for (2) Uterine prolapse (1)	NR	ALK+: 58 Desmin+: 48 SMA+: 43 Vimentin+: 5 CD68+: 4	NR	40
Makhlouf, 2002 <sup>47</sup>	Gastrointestinal tract	38	Male: 20 Female: 18 1.1:1	41 ± 23 <sup>p</sup>	Pain (14) Fever (7) GI bleeding (6) Obstruction (6) Intussusception (4)	Spindle cell proliferation in a collagenous or fibromyxoid stroma with infiltration of plasma cells, lymphocytes, eosinophils, and histiocytes	SMA+: 30 Vimentin+: 27 CD68+: 20 Desmin+: 2	NR	34
Neronov, 2020 <sup>48</sup>	Jaw-bone	25	Male: 12 Female: 13 1:1.1	34.8 ± 19.6 <sup>p</sup>	Bone destruction: (25) Soft tissue swelling (14) Ulcerated mucosa (4) Pain (8) Root resorption (7)	Spindle cell proliferation and infiltration of lymphocytes, plasma cells, neutrophils, and eosinophils	SMA+: 16 ALK+: 6 Vimentin+: 8 CD68+: 3 Desmin+: 1	Steroids 3/2	25
Masciocchi, 2011 <sup>49</sup>	Limbs (soft tissue)	7	Male: 6 Female: 1 6:1	57 (28–81) <sup>*p</sup>	NR	NR	SMA+: 7	NR	6

NR – Not reported,

\* Mean (range),

p – Pediatrics included