

# Does HIV co-infection promote *Echinococcus* dissemination?

K Couzens-Bohlin,  JEJ Krige,  P Keshaw,  H Allam,  E Jonas 

Surgical Gastroenterology Unit, Department of Surgery, Faculty of Health Sciences, Groote Schuur Hospital, University of Cape Town, South Africa

Corresponding author, email: eduard.jonas@uct.ac.za

## Summary

The influence of human immunodeficiency virus (HIV) on the severity of hepatic cystic echinococcosis (CE) is uncertain. HIV-modulated immune suppression may increase the risk of contracting CE with less self-limiting disease, more rapid progression, and a higher likelihood of complications. A 30-year-old male with concurrent, untreated HIV underwent surgery for two large, complicated hepatic CE cysts, which were replacing the right hemiliver, and innumerable peritoneal daughter cysts. At operation, 30 kg of cystic material was removed from the liver and peritoneal cavity. Despite postoperative complications, including cardiac arrest, respiratory failure, and a bile leak, the patient made a full recovery

**Keywords:** hepatic cystic echinococcosis, HIV

## Case report

A 30-year-old male of sober habits and no previous medical or surgical history presented to a rural clinic with a seven-year history of increasing abdominal distension and discomfort. On clinical examination, he was cachectic with a massively distended, non-tender, fluid-filled abdomen. Full blood count, serum electrolytes, and renal and liver function tests were within the normal reference ranges. An HIV test was positive with a CD4 count of 451 cells/ $\mu$ l and a viral load of 1 734 copies/ml. Screening for hepatitis B, hepatitis C, and tuberculosis were negative. A contrast-enhanced computed tomography (CT) scan showed two World Health Organization (WHO) type CE2 hepatic echinococcal cysts, 18.5 cm and 17.5 cm in maximum diameter, involving segments 5, 6, 7, and 8 (Figure 1a). In addition, innumerable peritoneal daughter cysts were present (Figure 1b), as well as an 8 cm left upper lobe pulmonary CE cyst (Figure 1c). The patient received a preoperative course of albendazole and started antiretroviral treatment.

At operation, both hepatic CE cysts were found to have ruptured before surgery (Figures 2a and 2b). Cystic material

weighing a total of 30 kg was evacuated from the peritoneal cavity along with the ruptured liver cysts (Figures 2b and 2c). The abdomen was irrigated with 5% Eusol and a dilute iodine solution, and the abdomen was closed after suction drains were placed in the liver cavities (Figure 2d).

The patient tolerated the operation well but experienced a cardiac arrest postoperatively, likely due to hypovolaemia. Cardiopulmonary resuscitation was performed, including the use of inotropes and intravenous fluids, and the patient recovered with no residual neurological deficit. He required postoperative ventilation for respiratory failure and treatment for refeeding syndrome. A postoperative bile leak was managed conservatively. He was discharged on antiretrovirals and albendazole after 20 days and was referred to thoracic surgery for removal of the pulmonary CE cyst. At the four-year follow-up, the patient was alive with no recurrence of CE.

## Discussion

*Echinococcus granulosus* follows a dog-sheep-dog cycle, where humans are accidental dead-end hosts.<sup>1-3</sup> The

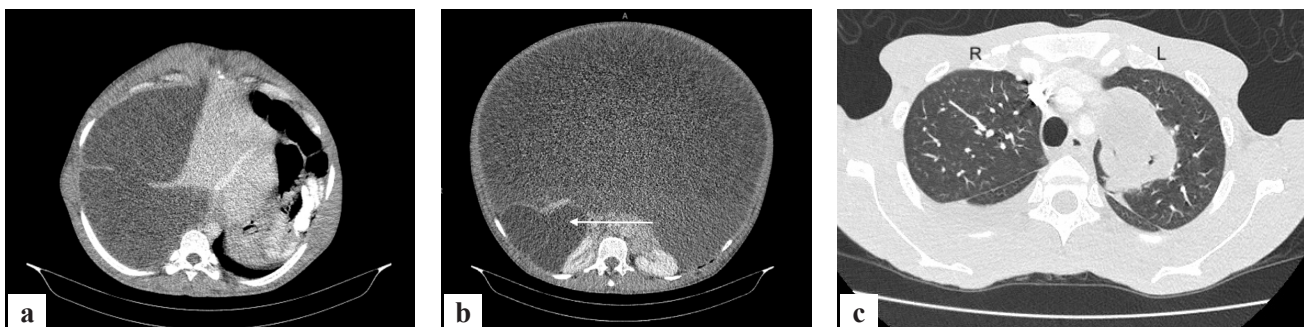

Figure 1: Contrast-enhanced CT images of a) liver cysts, b) massive abdominal distension due to thin-walled daughter cysts filling the peritoneal cavity, c) an 8 cm hydatid cyst in the left upper lung lobe

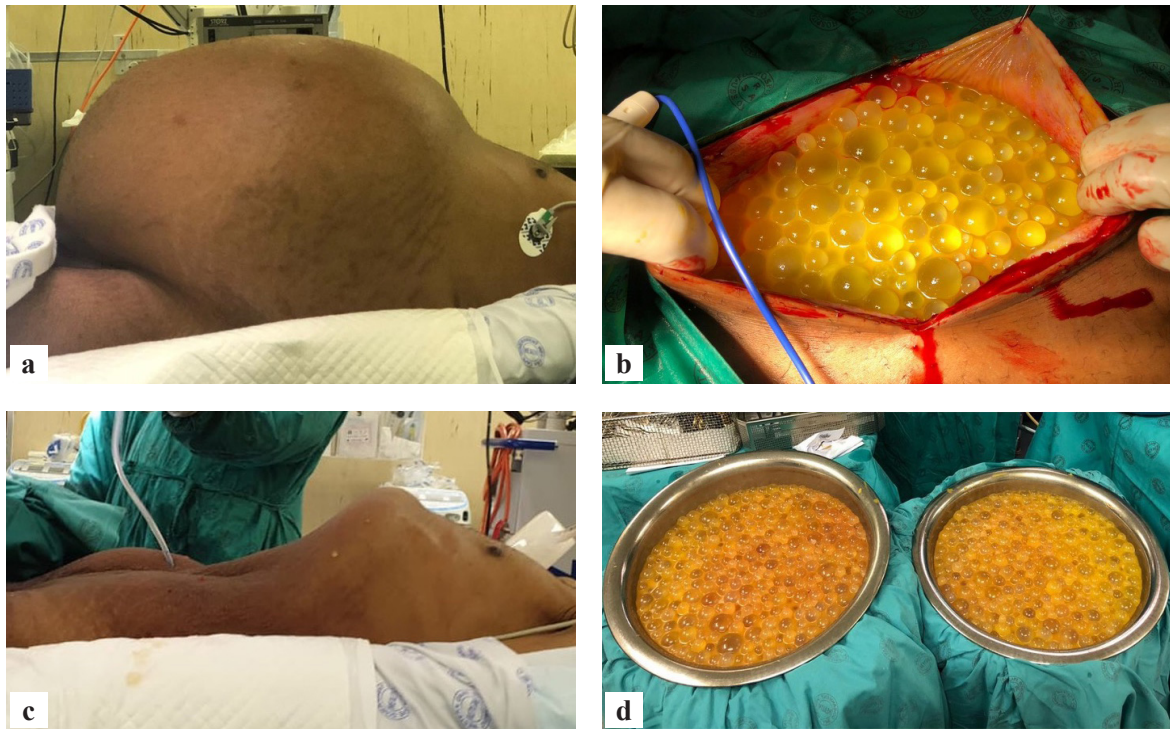


Figure 2: Peri-operative images of a) abdomen before cyst evacuation, b) peritoneal daughter cysts, c) abdomen after cyst evacuation, d) evacuated daughter cysts

infection results in fluid-filled echinococcal cysts containing immature tapeworms that predominantly involve the liver/lungs.<sup>1</sup> Some cysts are self-limiting and die, while others grow and develop daughter cysts, which may spread to other organs or rupture into the abdominal or pleural cavities.<sup>1</sup> Typically, CE has an asymptomatic incubatory period lasting several years, followed by non-specific symptoms such as weight loss, weakness, and abdominal distension and pain.<sup>3</sup> Nausea and vomiting may occur as the disease progresses with cyst enlargement.<sup>1,3</sup> Complications include secondary cyst infection, biliary obstruction due to pressure on the bile ducts or rupture of cysts into the biliary tree, and rarely, allergic reactions due to cyst rupture.<sup>1,2</sup>

Co-infections of HIV and CE are uncommon.<sup>4,5</sup> In South Africa, reliable data on CE prevalence is lacking.<sup>2</sup> The prevalence of CE in the Eastern Cape province is estimated to be as high as 11% and may be increasing.<sup>2,6</sup> With national HIV prevalence rates of around 13%, CE-HIV co-infection may be more common than documented.<sup>6-8</sup> Limited research suggests that CE is more severe with concomitant HIV, although the exact mechanism remains uncertain.<sup>4,6,7,9,10</sup> Untreated HIV suppresses the host immune defence against parasites by shifting to a Th2-dominant immune response and raises IL-10 levels with impaired helminth-specific effector cytokine function.<sup>6</sup> This increases tolerance for foreign antigens, resulting in increased disease acquisition, progression, and complications.<sup>5,6,9</sup> The rapid progression from symptom debut to massive parasitic infestation, as demonstrated in this patient, aligns with the hypothesis that HIV immunosuppression impairs the immune system's ability to self-limit CE or mount an antibody response.<sup>5,6</sup>

Hepatic CE management is complex, requiring surgery with pre- and postoperative anthelmintic treatment.<sup>3</sup> A postoperative mortality of 2.2% and relapse rates of 6.5% have been reported.<sup>1,3</sup> The hypothesis of exacerbated

morbidity in HIV-CE co-infection is clearly demonstrated in this patient who had a life-threatening complication, which he survived.<sup>4,6,7,9,10</sup> He presented with untreated HIV, which is not uncommon in South Africa, with up to 28% of HIV patients not receiving antiretroviral treatment.<sup>8</sup> The prevalence of HIV in CE patients presenting to our institution is around 50%, more than four times the prevalence in the wider population.<sup>7,8</sup> Therefore, apart from appropriate cross-sectional imaging, a full HIV work-up is necessary, including a viral load and CD4 count in HIV-positive patients.

## Conclusion

This case report suggests that patients with untreated HIV may present with more advanced and complicated CE. A better understanding of the pathogenesis of HIV-CE interaction may improve the management of CE in HIV-positive patients.






## Conflict of interest

The authors declare no conflict of interest.

## Ethical approval

The HHD registry (HREC/REF:R019/2016) and this study (HREC/REF:R244/2024) were approved by the Human Research Ethics Committee (HREC), Faculty of Health, University of Cape Town.

## ORCID

K Couzens-Bohlin  <https://orcid.org/0009-0006-7196-5805>  
 JEJ Krige  <https://orcid.org/0000-0002-7057-9156>  
 P Keshaw  <https://orcid.org/0009-0004-2880-0621>  
 H Allam  <https://orcid.org/0000-0001-5344-3532>  
 E Jonas  <https://orcid.org/0000-0003-0123-256X>

## REFERENCES

1. Thompson RCA. Biology and systematics of *Echinococcus*. *Adv Parasitol.* 2017;95:65-109. <https://doi.org/10.1016/bs.apar.2016.07.001>.
2. Karshima SN, Ahmed MI, Adamu NB, et al. Africa-wide meta-analysis on the prevalence and distribution of human cystic echinococcosis and canine *Echinococcus granulosus* infections. *Parasit Vectors.* 2022;15(357). <https://doi.org/10.1186/s13071-022-05474-6>.
3. who.int [Internet]. Echinococcosis. Geneva: World Health Organization; 2021. Available from: <https://www.who.int/news-room/fact-sheets/detail/echinococcosis>.
4. Ghasemirad H, Bazargan N, Shahesmaeili A, Harandi MF. Echinococcosis in immunocompromised patients: a systematic review. *Acta Trop.* 2022;232:106490. <https://doi.org/10.1016/j.actatropica.2022.106490>.
5. Von Braun A, Trawinski H, Wendt S, Lübbert C. Schistosoma and other relevant helminth infections in HIV-positive individuals—an overview. *Trop Med Infect Dis.* 2019;4(2):65. <https://doi.org/10.3390/tropicalmed4020065>.
6. Wahlers K, Menezes CN, Romig T, Kern P, Grobusch MP. Cystic echinococcosis in South Africa: the worst yet to come? *Acta Trop.* 2013;128(1):1-6. <https://doi.org/10.1016/j.actatropica.2013.06.002>.
7. Kloppers C, Couzens-Bohlin K, Bernon M, et al. Hydatid disease in South-Africa – is it a different disease in patients with HIV co-infection? *HPB (Oxford).* 2019;21(3):S593. <https://doi.org/10.1016/j.hpb.2019.10.235>.
8. [unaids.org](https://www.unaids.org) [Internet]. UNAIDS data 2021. Geneva: UNAIDS Joint United Nations Programme on HIV/AIDS; 2021. Contract No.: Licence: CC BY-NC-SA 3.0 IGO. Available from: [https://www.unaids.org/sites/default/files/media\\_asset/JC3032\\_AIDS\\_Data\\_book\\_2021\\_En.pdf](https://www.unaids.org/sites/default/files/media_asset/JC3032_AIDS_Data_book_2021_En.pdf).
9. Javed A, Kalayarsan R, Agarwal AK. Liver hydatid with HIV infection: an association? *J Gastrointest Surg.* 2012;16(6):1275-7. <https://doi.org/10.1007/s11605-011-1713-5>.
10. Ran B, Shao Y, Guo Y, et al. Surgical treatment of hepatic cystic echinococcosis in patients co-infected with HIV/AIDS. *J Helminthol.* 2016;90(1):125-8. <https://doi.org/10.1017/S0022149X15000188>.