

Rectal suction biopsies to diagnose Hirschsprung's disease in a low-resource environment – optimising cost-effectiveness

L Hartford,¹ N Schönfeldt,¹ R Mohanlal,^{2,3} C Bebington,¹ J Loveland,¹ C Westgarth-Taylor,¹ G Brisighelli¹

¹ Paediatric Colorectal and Pelvic Reconstruction Centre, Department of Paediatric Surgery, Chris Hani Baragwanath Academic Hospital, University of the Witwatersrand, South Africa

² Department of Anatomical Pathology, University of the Witwatersrand, South Africa

³ Chris Hani Baragwanath Laboratory, National Health Laboratory Services, South Africa

Corresponding author, email: leilahartford@gmail.com

Background: The diagnosis of Hirschsprung's disease (HD) by rectal suction biopsy (RSB) has cost implications that could be reduced by ascertaining the optimal number of specimens required. The aim was to audit our experience to optimise cost-effectiveness.

Methods: Medical records of all patients who underwent an RSB between January 2018 and December 2021 were reviewed. In 2020, we transitioned from using the Solo-RBT to the rbi2 system (requiring single-use cartridges). Descriptive statistics were reported and a comparative analysis of the diagnostic efficacy of the Solo-RBT versus the rbi2 system was performed. The cost of consumables was calculated according to the number of specimens submitted.

Results: Of 218 RSBs, 181 were first and 37 were repeat. The mean age at biopsy was 62 days (IQR 22–65). An average of two tissue specimens were obtained per biopsy. Of the 181 first biopsies, 151 were optimal and 30 suboptimal. HD was confirmed in 19 (10.5%) of the patients. Amongst biopsies where a single specimen was obtained, 16% were inconclusive, compared to 14% with two specimens and 5% with three specimens. The cartridges for the rbi2 system cost R530. If two cartridges are used at initial biopsy the total cost is double of a single tissue specimen sent for initial biopsy, and two specimens sent for repeat biopsies.

Conclusion: In a low-resource setting, selecting the appropriate RSB system and obtaining a single specimen is sufficient to diagnose HD. Patients with inconclusive results should undergo a repeat biopsy where two specimens are obtained.

Keywords: Hirschsprung's disease, rectal suction biopsy, rectal biopsy

Introduction

Hirschsprung's disease (HD) is a congenital condition characterised by absence of ganglion cells and hypertrophied nerve trunks in the colon, causing a functional distal bowel obstruction.¹ It is prudent to investigate for HD in newborns with failure of passage of meconium in the first 24 hours of life, abdominal distension and bilious vomiting.² The older child with HD may present with chronic constipation and failure to thrive. In addition to these clinical features, plain abdominal radiograph, contrast enema, anorectal manometry and abdominal ultrasound can be useful to identify patients who may require biopsy and help to exclude other differential diagnoses.² Ultimately, to diagnose HD a histological confirmation is required.³

The consequences of missing a diagnosis of HD can be devastating with complications including malnutrition, bowel obstruction, Hirschsprung's associated enterocolitis, bowel perforation and death.⁴ Due to the long-term sequelae associated with a missed diagnosis of HD, it is imperative to make the diagnosis early and definitively. The diagnosis of HD however can be challenging as it relies on histological confirmation of absence of enteric ganglion cells in the myenteric and submucosal plexus of the distal rectum.

The gold standard technique for obtaining this biopsy specimen in infants is the rectal suction biopsy (RSB) which was first described in 1969 by Noblett.⁵ This technique has been widely adopted as it can be performed safely in the ward or as an outpatient procedure without the need for anaesthesia. In contrast, a full-thickness rectal biopsy requires general anaesthesia and is performed in theatre.

There are a number of different RSB devices available, each with its own advantages and disadvantages, including the multipurpose suction biopsy kit, Rubin tube, model SBT-100, Solo-RBT or the rbi2 systems. Many of the older systems are reusable but are prone to breaking and require expensive repairs whereas the newer systems tend to break less but require the use of single-use capsules, where one tissue specimen is obtained per capsule.⁶

For a biopsy to be sufficient the tissue specimen should be at least 3 mm in size with at least one-third submucosa.⁷ There is no standardisation regarding the number of specimens that should be taken to make a diagnosis. A systematic review of RSBs by Friedmacher found that specimen quantity varied considerably with a median of 2 (range 1–8) specimens per RSB.⁸

In a low-resource setting, access to biopsy equipment (including consumables) is limited, therefore the aim

of our study was to explore how we could improve cost-effectiveness, by determining how many specimens, where one capsule is used per specimen, were required to accurately diagnose and exclude HD. To achieve this aim, the specific objectives of our study were to determine the overall incidence of HD in the study population, to determine the diagnostic efficacy of the RSB according to how many tissue specimens were submitted, and finally to develop a strategy to prevent unnecessary expenditure on capsules.

Methods

We performed a retrospective review of the medical records of patients who underwent RSB at Chris Hani Baragwanath Academic Hospital (CHBAH) in the department of paediatric surgery between January 2018 and December 2021. The dates were chosen due to the availability and reliability of patient records in this time frame. No formal sample size calculation was conducted. In 2020, our department transitioned from using a re-usable Solo-RBT gun to the rbi2 system which makes use of single-use capsules. All RSBs were performed by doctors under the supervision of a specialist paediatric surgeon.

The biopsy specimens were submitted to the CHBAH histopathology department, where histological examination of haematoxylin and eosin-stained slides cut from formalin-fixed paraffin-embedded tissue is performed in cases of suspected HD. Serial sections are cut through the tissue block as indicated. Acetylcholinesterase histochemistry is not performed here. Absence of ganglion cells and the presence of hypertrophied nerve fibres (> 40 µm in diameter) in an adequate biopsy confirms the diagnosis of HD.⁷

Any child who underwent RSB between January 2018 and December 2021 was considered for inclusion. Patients were excluded if the initial biopsy taken was not RSB, or if the initial RSB was inconclusive and the patient demised before a histological diagnosis (either by repeat RSB, full-thickness rectal biopsy or other biopsy) could be obtained. For each patient who underwent biopsy, the number of tissue specimens taken at initial biopsy and the number of times the biopsy needed to be repeated were recorded.

Making use of the CHBAH colorectal clinic data record keeping system and the departmental weekly electronic admission statistics list, we identified all patients who were investigated for HD in the study period. Patients were identified for biopsy based on a variety of factors such as a suggestive clinical history (delayed passage of meconium, abdominal distension and bilious emesis), examination findings (abdominal distension and explosive stooling on rectal examination) and radiological findings (suggestive contrast enema and abdominal radiograph). The National Health Laboratory Service (NHLS) database was accessed to determine whether these patients underwent an RSB. The histopathology reports of all of the potentially eligible patients were obtained and the following data were abstracted:

- Age at biopsy
- Number of tissue specimens provided
- Biopsy result
- Need for repeat biopsy

All data was anonymised and entered and stored on a password-protected Excel spreadsheet for the duration of the study period. After completion of the data analysis, a copy of the cleaned and coded raw data was provided to the

department of paediatric surgery research office, where it will be securely stored in a repository.

Descriptive statistics including the mean age at diagnosis and the mean number of tissue specimens per biopsy were computed in Excel. A specimen was defined as inadequate if it was too small or contained inadequate submucosa for histological diagnosis. The diagnostic efficacy was defined as sufficient specimen to determine the presence or absence of ganglion cells, and therefore either diagnose or exclude HD. A comparative analysis between biopsies done in 2018 and 2019 to biopsies done in 2021 was performed using a Fisher's exact test in Statistica™ (Version 13.2, Statsoft). For this comparative analysis, we excluded biopsies done in 2020 as this was considered an overlap period where both biopsy systems were in use, and we could not definitively say which system was used for each biopsy. Finally, we calculated the estimated cost of the consumables used for these biopsies according to how many specimens were submitted per biopsy.

Results

A total of 218 RSBs were performed in the study period. Of these, 181 were first biopsies and 37 were repeat biopsies. The mean age at biopsy was 62 days (IQR 22–65). An average of two specimens (range 1–6) per biopsy were sent to the pathologists. In 40% of patients, a single tissue sample was submitted, two specimens were submitted in 30% of patients and three specimens in 20% of patients (Table I).

The diagnostic efficacy, defined as sufficient specimen to determine the presence or absence of ganglion cells, of first RSB was 83%, (150/181). The remaining 17% (30/181) were labelled as suboptimal.

Of the 181 first-time biopsies, 139 patients were considered HD negative and 12 HD positive. Thirty biopsies were considered suboptimal by the pathologist, with 14 being too superficial, eight too distal, six suspicious of HD but it could not be confirmed and two were crushed. Because of clinical suspicion, four patients in the HD-negative group had confirmatory repeat biopsies. For the same reason, four patients in the HD-positive group had a repeat biopsy, that confirmed the diagnosis in three patients and excluded it in one. Of the 30 suboptimal biopsies, at repeat biopsy, HD was diagnosed in eight patients and excluded in 14. Five patients did not undergo repeat biopsy and three had suboptimal repeat biopsies. Ultimately, 19 patients were diagnosed with HD, representing 10.5% of the patients who underwent an RSB during our study period (Figure 1).

Table II demonstrates that for those biopsies where a single specimen was submitted, the diagnostic efficacy was 84%. When two specimens were submitted, the diagnostic

Table I: Number of tissue samples taken per biopsy

Number of samples	Number of patients	Percentage
1	88	40
2	67	30
3	44	20
4	13	6
5	4	2
6	1	1
Multiple	1	1
Total	218	100

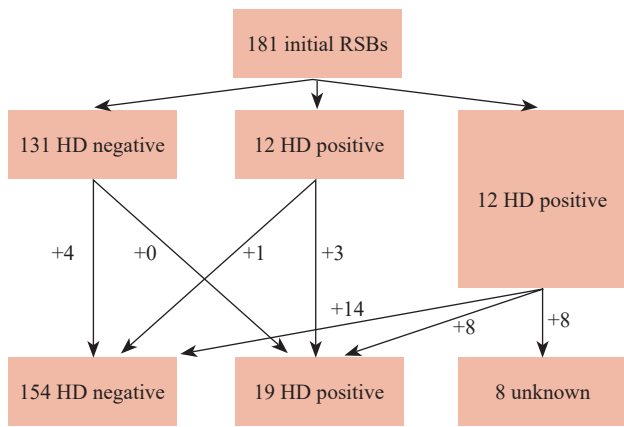


Figure 1: Diagnostic efficacy of initial RSB including need for re-biopsy

Table II: Number of specimens and diagnostic efficacy of RSB

Number of specimens	Inconclusive biopsies	Conclusive biopsies	Diagnostic efficacy
1	11/69	58/69	84%
2	8/56	48/56	86%
3	2/38	36/38	95%
4	3/12	9/12	75%
5	1/3	2/3	67%
6	0/1	1/1	100%

efficacy was 86%. When comparing biopsies done with the RBT Solo gun (in 2018 and 2019, $n = 123$) to biopsies done with the rbi2 system ($n = 37$) there was a significant difference in the number of biopsies where a single specimen was submitted to pathology (30% vs 81%, $p < 0.001$). However, there was no statistically significant difference in the diagnostic efficacy of the initial biopsy (87% using the

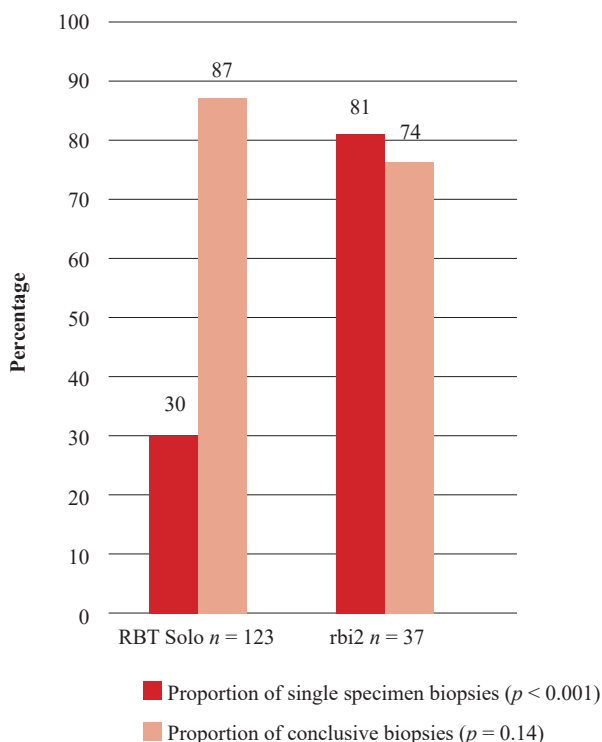


Figure 2: Proportion of single-specimen biopsies and diagnostic adequacy of RBT Solo versus rbi2 systems

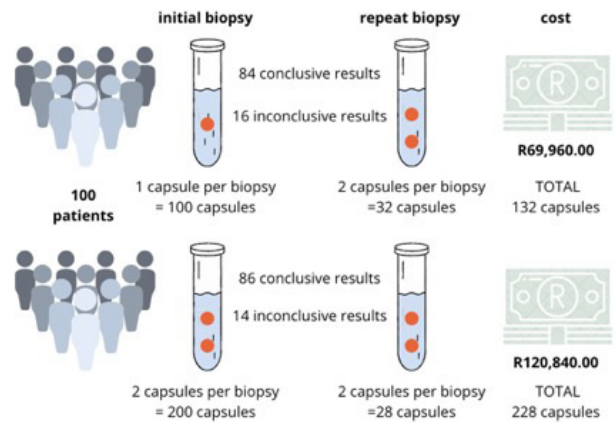


Figure 3: Example of cost of consumables for RBI system if a single specimen compared to two specimens is obtained

RBT Solo gun, compared to 76% using the rbi2, $p = 0.14$) (Figure 2).

From this data we calculated that, using the RBI system, with a consumable cost of R530 per capsule, for every 100 patients that are investigated for HD, using the two specimens per biopsy approach, 14 patients would require a repeat biopsy. Ultimately, a total of 228 capsules would be required, amounting to over R120 840. However, if we were to take an approach where a single specimen is submitted at initial biopsy, and then two specimens submitted for the 16 patients who require a repeat biopsy, only 132 capsules would be required. This would amount to a cost of R69 960 (Figure 3).

Discussion

Of all patients who underwent an RSB during our study period, 10.5% were diagnosed with HD. This is on the lower end of the range reported in the international literature (10–25%).⁸ This may represent over-investigation of infants with symptoms of HD.⁸ However, we believe that, in our setting where access to healthcare services is challenging, it is safer to over-investigate the symptomatic child, as the consequence of missing a diagnosis of HD could result in significant morbidity or mortality.

The overall diagnostic efficacy of initial RSB in our setting was 83%, which is in line with international literature.⁹ In a review of 58 studies, the pooled diagnostic efficacy of 14 053 RSBs was 89.93% (CI 89.11–90.70%).⁸ The diagnostic efficacy of RSB was not significantly different with a single specimen compared to when two specimens were submitted to the pathologists (84% vs 86%). For biopsies where three or more specimens were submitted, the numbers were too small to draw any significant conclusions. It is also likely that when several specimens were submitted the surgeon performing the biopsy may not have been satisfied with the adequacy of the initial specimen.

A limitation of our study is that we were unable to control for the individual performing the procedure. Biopsies were all performed by doctors; however, data on the level of training or experience of the individual performing the biopsy were not available. We were unable to account for the possibility that the number of specimens submitted to the pathologists may not represent the actual number of capsules used to obtain these specimens, as sufficient training is required to learn to use the RBI system to obtain an adequate biopsy using a single capsule.

As we only studied the two systems we had used at our institution, we do not know how the other systems available on the market would fare. This is a limitation as there may be other systems that are more cost-efficient and accurate.

There is no internationally agreed-upon scoring system to determine which children should undergo biopsy. In the literature, there are several risk factors that may increase the risk of suspicion of HD such as male sex, failure to thrive, gross abdominal distention plus vomiting, and fulfilling the Rome 4 criteria for functional constipation.¹⁰ Most clinicians also use adjuncts such as contrast enema before going on to RSB.⁴ Developing a scoring system which integrates risk factors, clinical findings and radiological evaluations would be very relevant and a potential future endeavour.

However, until such a system is developed and supported with evidence, we recommend performing an RSB in any child with a high clinical suspicion as the adverse effects are minimal in comparison to the potential morbidity and mortality associated with missing a diagnosis of HD, particularly in our context where access to paediatric surgical care is scarce.

Conclusion

In conclusion, HD was diagnosed in 10.5% of the patients that underwent an RSB in our facility during the study period. The overall diagnostic efficacy of RSB for initial biopsy was 83% during the study period. Using the rbi2 system with disposable capsules, and providing a single specimen per biopsy still allows a high diagnostic efficacy while minimising costs.

Conflict of interest


The authors declare no conflict of interest.

Ethical approval

Ethical approval for this study was obtained from the Human Research Ethics Committee Medical at the University of the Witwatersrand (M220137) and the NHLS Academic Affairs and Research Department.


ORCID

L Hartford  <https://orcid.org/0000-0001-7120-8827>

R Mohanlal  <https://orcid.org/0000-0001-9422-1303>

J Loveland  <https://orcid.org/0000-0002-3341-0749>

C Westgarth-Taylor  <https://orcid.org/0000-0002-6416-6195>

G Brisighelli  <https://orcid.org/0000-0002-5449-7820>

REFERENCES

1. Jensen AR, Frischer JS. Surgical history of Hirschsprung disease. *Sem Pediatr Surg.* 2022;31(2):151174. <https://doi.org/10.1016/j.sempedsurg.2022.151174>.
2. Kyrklund K, Sloots CE, De Blaauw I, et al. ERNICA guidelines for the management of rectosigmoid Hirschsprung's disease. *Orphanet J Rare Dis.* 2020;15(1):1-16. <https://doi.org/10.1186/s13023-020-01362-3>.
3. Marei MM, Abdelsattar AH, Yassin TM, et al. Reducing the frequency of unnecessary rectal biopsies by combined interpretation of clinical and radiological findings in Egyptian children with suspected Hirschsprung's disease. *Gaz Egypt Pediatr Assoc.* 2015;63(3-4):80-85. <https://doi.org/10.1016/j.epag.2015.07.001>.
4. Allen AR, Putnam AR, Presson AP, et al. Accuracy of suction rectal biopsy for diagnosis of Hirschsprung's disease in neonates. *Eur J Pediatr Surg.* 2019;29(05):425-30. <https://doi.org/10.1055/s-0038-1667040>.
5. Noblett HR. A rectal suction biopsy tube for use in the diagnosis of Hirschsprung's disease. *J Pediatr Surg.* 1969;4(4):406-9. [https://doi.org/10.1016/0022-3468\(69\)90606-X](https://doi.org/10.1016/0022-3468(69)90606-X).
6. Prato AP, Martucciello G, Jasonni V. Solo-RBT: a new instrument for rectal suction biopsies in the diagnosis of Hirschsprung's disease. *J Pediatr Surg.* 2001;36(9):1364-6. <https://doi.org/10.1053/jpsu.2001.26370>.
7. Kapur RP. Practical pathology and genetics of Hirschsprung's disease. *Semin Pediatr Surg.* 2009;18(4):212-23. <https://doi.org/10.1053/j.sempedsurg.2009.07.003>.
8. Friedmacher F, Puri P. Rectal suction biopsy for the diagnosis of Hirschsprung's disease: a systematic review of diagnostic accuracy and complications. *Pediatr Surg Int.* 2015;31(9):821-30. <https://doi.org/10.1007/s00383-015-3742-8>.
9. Hall NJ, Kufeji D, Keshtgar A. Out with the old and in with the new - a comparison of rectal suction biopsies with traditional and modern biopsy forceps. *J Pediatr Surg.* 2009;44(2):395-8. <https://doi.org/10.1016/j.jpedsurg.2008.10.093>.
10. Jaroy EG, Emblem R, Reims HM, Risa GT, Ougland R. Evaluation of diagnostic factors used to refer children with constipation for rectal biopsies. *Int J Colorectal Dis.* 2022;37(3):597-605. <https://doi.org/10.1007/s00384-021-04069-4>.