

Open surgical treatment for giant presacral tailgut cyst – a case report

Q Liu,¹ P Guo,² C Li,² G Yu,² J Jiao²

¹ School of Clinical Medicine, Shandong Second Medical University, China

² Department of Gastrointestinal Surgery, Central Hospital Affiliated to Shandong First Medical University, China

Corresponding author, email: jiejiao123@outlook.com

Summary

Tailgut cyst is an exceedingly rare congenital anomaly originating from embryonic remnants of the tailgut. Owing to its asymptomatic nature in the early stages, it is prone to clinical misdiagnosis. We present a case of a 55-year-old female with initial symptoms manifesting as sacrococcygeal pain. Magnetic resonance imaging (MRI) revealed a multilocular cystic lesion, prompting preoperative suspicion of an enormous tailgut cyst. Following a comprehensive assessment, an open posterior approach with coccygectomy was chosen, proving to be a safe and effective surgical technique, particularly for large, low-lying tailgut cysts.

Keywords: enormous mass, tailgut cyst, open posterior approach, case report

Case report

A 55-year-old woman presented in March 2023 with persistent sacrococcygeal pain for 6 months. Characterised by intermittent stabbing sensations, the pain worsened when sitting or lying down, improving during standing or walking, with no radiation to the lower back or perineum. The patient had regular bowel movements with no abnormality in stool characteristics. Physical examination revealed tenderness at the coccygeal tip. Digital rectal examination identified a round mass located 4 cm inside the rectum wall, with limited mobility. Pelvic computed tomography (CT) imaging revealed an anteriorly located multilocular mass in the sacrococcygeal region, measuring approximately 95 × 120 × 75 mm, with internal fat infiltration and calcifications. Contrast-enhanced

MRI depicted a multilocular cystic mass located posterior to the rectum, anterior to the sacrococcygeal bones, extending from the third sacral vertebra (S3) to below the coccygeal tip. The mass displayed low signal intensity on T1-weighted imaging, high signal intensity on T2-weighted imaging, internal fat infiltration, restricted diffusion, and anterior displacement of the rectum due to compression (Figure 1). Tumour markers CA-125, CA19-9, and CEA were within normal ranges.

Preoperative imaging diagnosis considered a teratoma or presacral tailgut cyst. The decision was made for a presacral approach for mass excision surgery. After endotracheal intubation under general anaesthesia, the patient was positioned in the prone jackknife position. A transverse S-shaped incision was made over the surface of the coccyx.

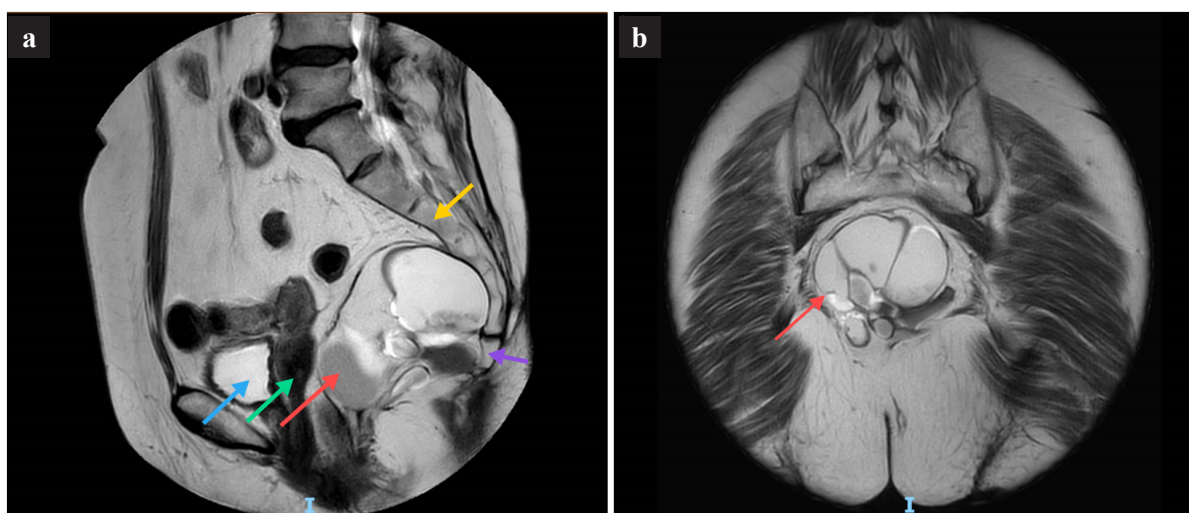


Figure 1: MRI a – T2WI sagittal position: The mass (red arrow) extends from the third sacral vertebra (yellow arrow) to the coccyx (purple arrow). Surrounding anatomical structures include the rectum (green arrow) and the bladder (blue arrow). b – T2W-TSE (Turbo Spin Echo) coronal position: The mass appears multilocular (red arrow).

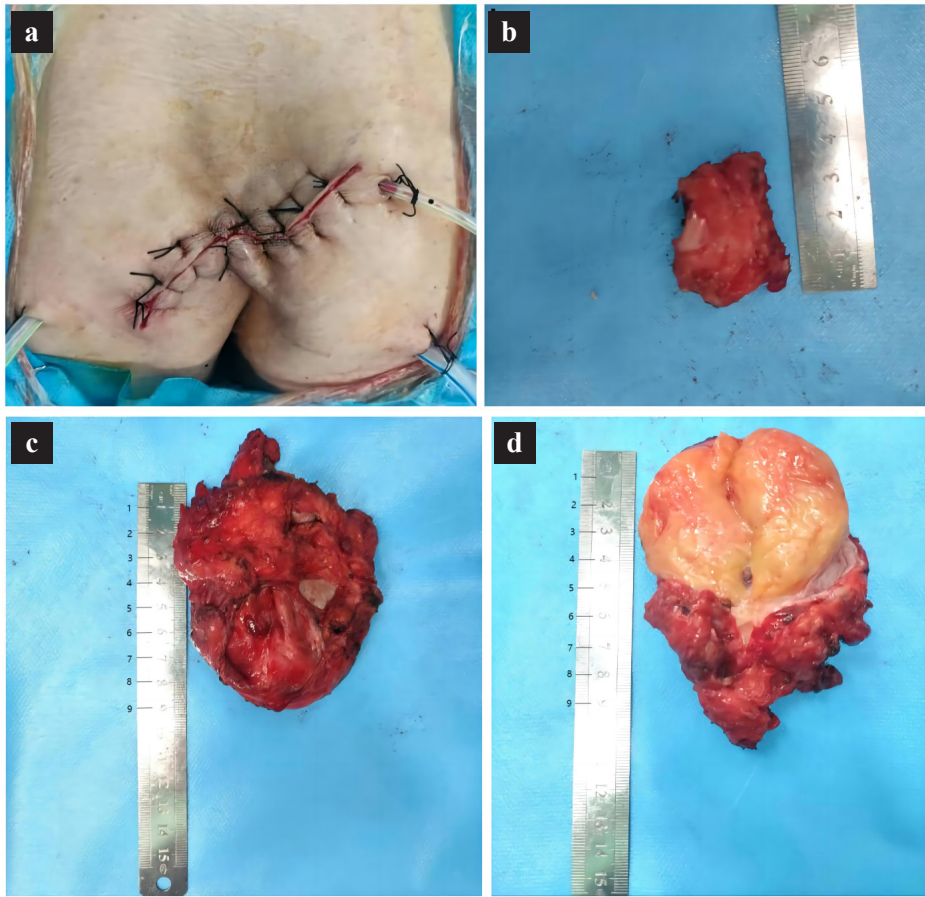


Figure 2: a – Postoperative drains; b – Coccyx; c – Specimens that have been excised after surgery; d – Longitudinal dissection of the specimen

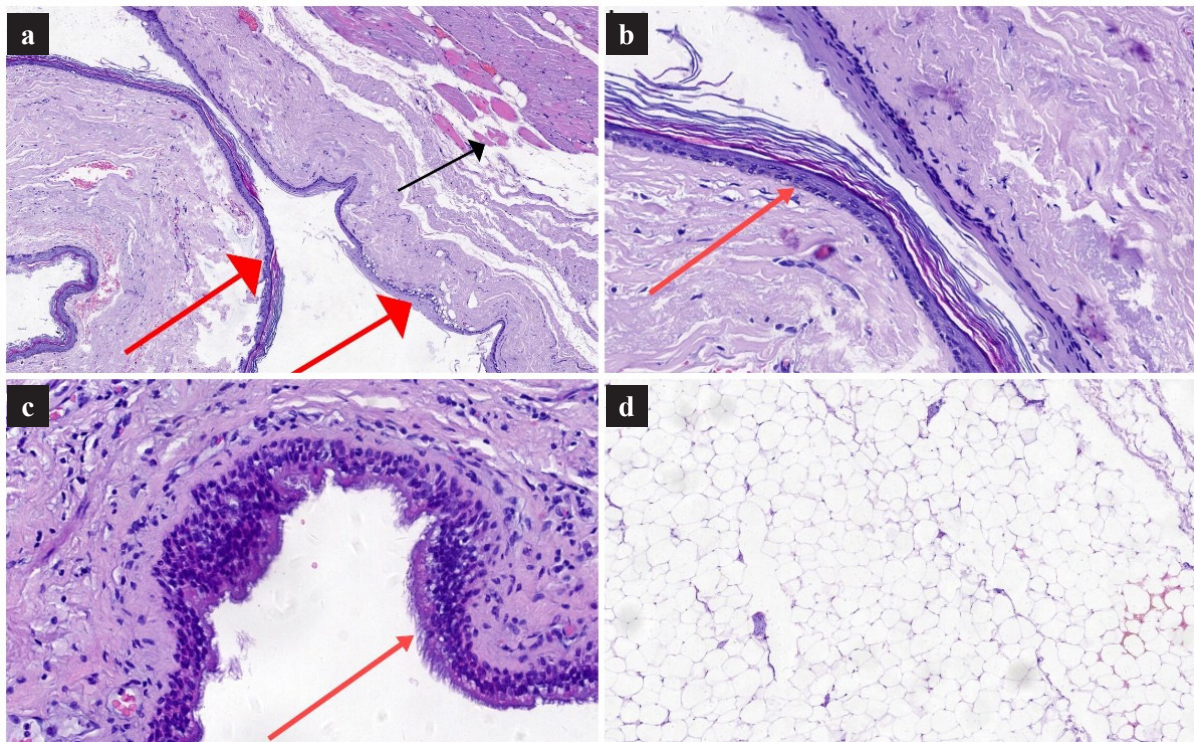


Figure 3: a – Morphological observation of multilocular cystic areas (red arrows) and smooth muscle (black arrow); b – The cyst wall was lined with squamous cells (red arrow); c – The cyst wall was lined with ciliated columnar epithelium cells (red arrow); d – Adipose tissue in solid areas

Layer by layer, the skin and subcutaneous tissue were excised, revealing a cystic-solid mass. Densely adhered to the coccygeal periosteum, the mass required coccygectomy for complete exposure. Guided by digital rectal examination, a combination of blunt and sharp dissection was employed to achieve total excision. For optimal drainage and infection prevention, two negative-pressure drainage tubes were placed in the residual cavity, and an additional negative-pressure drainage tube was inserted into the subcutaneous tissue of the incision. The surgery lasted for 120 minutes and proceeded smoothly. The surgically resected specimens were subjected to pathological examination (Figure 2). Gross pathological examination showed that the tumour was multilocular with cystic and solid components (Figure 3). Morphologically, the cystic area was lined by squamous cells and ciliated columnar epithelium cells, and there were scattered smooth muscle, nerve plexus and adipose tissue in the cyst wall, with lymphocyte infiltration and hemosiderin deposition in the stroma. Whereas the solid area was mainly adipose tissue. In addition, immunohistochemical results showed that the epithelial cells were positive for CK and EMA, some epithelial cells were positive for Villin, and the nerve plexus was positive for S-100. No evidence of malignant transformation was observed in the pathological examination. The patient recovered and was discharged 12 days postoperatively. Subsequent telephonic follow-up over 10 months revealed no significant complaints or recurrence.

Discussion

Tailgut cyst is a congenital multicystic lesion, mostly located in the presacral space behind the rectum, and some scholars believe that its aetiology is related to abnormal embryonic development of the tailgut.^{1,2} The tailgut, the farthest part of the embryonic intestine, usually regresses as embryonic development progresses, but its remnants may persist in the presacral area, leading to the formation of tailgut cyst.¹

Due to its extreme rarity in clinical practice, the true incidence of this condition is challenging to quantify accurately. Most patients are between 30 and 60 years old, with a higher prevalence in females, possibly 3 to 5 times more than in males.³

Epidemiological studies indicate that in the early stages, most lesions are asymptomatic. However, when the mass compresses adjacent tissues and organs, it may cause various nonspecific symptoms, such as difficulty in defecation, urinary frequency, urinary retention, lower abdominal pain, and sciatic nerve pain.^{2,4} In this case, the patient's initial symptom was sacrococcygeal pain, possibly due to compression of the coccygeal nerve plexus by the mass.

Rectal cysts may be easily confused with other conditions, such as epidermoid cysts, dermoid cysts, teratomas, spinal dermoids, or inflammatory cysts, highlighting the critical importance of an accurate diagnosis.⁵ Both CT scan and MRI serve as valuable imaging modalities for diagnosing rectal cysts. CT scan provides clear visualisation of characteristic features, such as uniform cystic density and well-defined borders. MRI, surpassing CT in diagnostic value and preoperative assessment, offers higher contrast resolution, allowing precise determination of the extent of cystic masses and their relationships with surrounding structures. MRI is also helpful in distinguishing between unilocular and multilocular cystic masses, with rectal cysts typically presenting as multilocular. Cysts often exhibit

low signal intensity on T1-weighted images and high signal intensity on T2-weighted images.⁶ The presence of high protein content, mucoid material, or intracystic haemorrhage may suggest malignancy, appearing as high signal intensity on T1-weighted images. Therefore, MRI assists in determining whether malignant transformation or associated infections have occurred.^{2,6} Histopathology serves as the "gold standard" for diagnosing rectal cysts, and the current consensus involves surgical excision of the identified mass, followed by gross pathological and histopathological assessments.⁷

Complete surgical excision is the preferred and effective treatment for this condition. However, due to the extreme rarity of the disease, the initial diagnosis is challenging. Inappropriately chosen surgical methods that fail to completely remove the lesion may lead to a risk of recurrence, necessitating cautious consideration by clinicians. The choice of surgical approach depends on factors such as lesion size, location, and the presence of complications. Common options include laparoscopic minimally invasive surgery and open surgery. Laparoscopic surgery offers advantages such as minimally invasive procedures, reduced bleeding, and fewer complications, often used for anterior approaches (abdominal).⁸ However, in this case, the lesion is positioned low, below S3, and the narrow space in the presacral region, coupled with the substantial size of the mass, presents risks of poor exposure and operational difficulties in both anterior and posterior laparoscopic approaches. Consequently, an open surgical approach was adopted for this patient. The advantages of an open approach through the sacrococcygeal route include providing an excellent surgical field of view, ensuring thorough excision, and high safety for the majority of low rectal cysts.⁹ Recently, literature has reported on robot-assisted surgical removal of rectal cysts, which, compared to laparoscopy, demonstrates better reduction of tissue damage and recurrence risk. However, it also has disadvantages, such as high costs, a steep learning curve, and extended surgical durations.¹⁰

In conclusion, this case underscores the efficacy of complete surgical excision in managing symptomatic tailgut cysts and preventing recurrence. Specifically, employing an open posterior surgical approach with coccygectomy proved effective in addressing a large, low-lying tailgut cyst.

Conflict of interest

The authors declared no competing interest.

Funding source


This work was supported by the Science and Technology Development Programme of Jinan Municipal Health Commission (Grant No. 2019-2-06,2023-2-18;2023-2-17;2023-1-10).


Patient consent


Informed consent was obtained and signed by this patient.


ORCID

Q Liu  <https://orcid.org/0009-0008-9996-5502>

P Guo  <https://orcid.org/0009-0008-7074-5899>

C Li  <https://orcid.org/0000-0002-2633-3124>

G Yu  <https://orcid.org/0009-0001-9931-1866>

J Jiao  <https://orcid.org/0000-0003-2652-8930>

REFERENCES

1. Levert LM, Van Rooyen W, Van Den Bergen HA. Cysts of the tailgut. *Eur J Surg.* 1996;162(2):149-52.
2. Aflalo-Hazan V, Rousset P, Mourra N, et al. Tailgut cysts: MRI findings. *Eur Radiol.* 2008;18(11):2586-93. <https://doi.org/10.1007/s00330-008-1028-4>.
3. Hjermsstad BM, Helwig EB. Tailgut cysts: Report of 53 cases. *Am J Clin Pathol.* 1988;89(2):139-47. <https://doi.org/10.1093/ajcp/89.2.139>.
4. Moshtaghian M, Shahsiah R, Jafari F, Aghili M. Malignant transformation of tailgut cyst to squamous cell carcinoma, a rare case with poor outcome. *Clin Case Rep.* 2023;11(2):e6893. <https://doi.org/10.1002/ccr3.6893>.
5. Brown IS, Sokolova A, Rosty C, Graham RP. Cystic lesions of the retrorectal space. *Histopathology.* 2023;82(2):232-41. <https://doi.org/10.1111/his.14769>.
6. Liang F, Li J, Yu K, et al. Tailgut cysts with malignant transformation: Features, diagnosis, and treatment. *Med Sci Monit.* 2020;26:e919803. <https://doi.org/10.12659/MSM.919803>.
7. Hufkens AS, Cools P, Leyman P. Tailgut cyst: report of three cases and review of the literature. *Acta Chir Belg.* 2019;119(2):110-7. <https://doi.org/10.1080/00015458.2017.1353758>.
8. Kwak HD, Kim CH. Tailgut cyst, report of 24 cases single center experience. *Ann Coloproctol.* 2019;35(5):227-8. <https://doi.org/10.3393/ac.2019.10.14>.
9. Sakr A, Kim HS, Han YD, et al. Single-center experience of 24 cases of tailgut cyst. *Ann Coloproctol.* 2019;35(5):268-74. <https://doi.org/10.3393/ac.2018.12.18>.
10. Bulisani BM, Gomes LGL, Leite MAO, et al. Robotic approach to remove four tailgut cyst cases in Brazil: a case series. *Einstein (Sao Paulo).* 2023;21:eRC0544. https://doi.org/10.31744/einstein_journal/2023RC0544.