

Incarcerated trans-stomal herniation resembling a stomal prolapse – a case report

N Shaikh,  RV Blanco,  M Vente,  R Ebrahim 

Robert Mangaliso Sobukwe Hospital, South Africa

Corresponding author, email: naeemshaikh1@gmail.com

Summary

Trans-stomal herniation, where abdominal contents protrude through the stomal aperture and lie between the two intestinal walls of the stoma is a very rare complication of stomas and can resemble a stomal prolapse. We describe a unique case of a stomal prolapse and concurrent trans-stomal small bowel herniation, which required emergency stoma refashioning for incarceration.

Keywords: stomal aperture, trans-stomal herniation, stomal prolapse, emergency stoma refashioning

Case report

A healthy 35-year-old male presented in 2018 with Fournier's gangrene and secondary peri-anal involvement. His medical history was unremarkable except for smoking. An extensive peri-anal wound debridement was required to treat the sepsis. To facilitate wound healing, a diverting sigmoid loop colostomy was fashioned in the left lower quadrant, above the iliac spine. The peri-anal wound healed well in the subsequent months and the patient was evaluated in the outpatient department for a reversal of his colostomy.

During this period the patient presented with prolapse of the stoma. The stoma was easily reduced and showed no further complications, so was managed non-operatively while awaiting the reversal.

The patient presented a few months later with an engorged prolapsed stoma and symptoms of bowel obstruction. He reported severe pain at the prolapsed stoma site and mentioned that a coughing episode had precipitated the onset of the prolapse. On examination he had moderate generalised abdominal tenderness and decreased bowel sounds. His vital signs were within normal range, although his blood pressure was slightly elevated at 130/86 mmHg.

The apparent stomal prolapse measured approximately 15 cm and the stoma was engorged, erythematous and oedematous. Abdominal X-ray revealed distended bowel loops and residual contrast from a previous barium loopogram (Figure 1).

Manual reduction was unsuccessful. A second attempt with gentle manual pressure to the protruding portion, aided by application of a topical osmotic agent (50% dextrose and normal saline solution) to reduce the oedema, also failed. Within two hours, the stoma displayed signs of ulceration and imminent necrosis (Figure 2a). The patient was scheduled for an emergency local refashioning of the stoma.

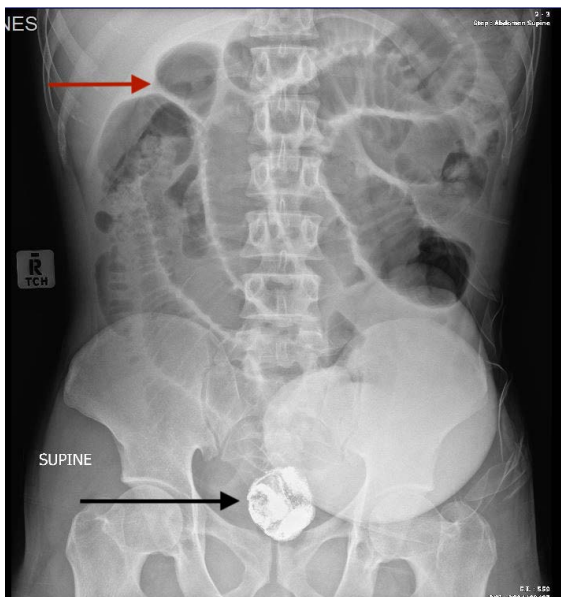


Figure 1: Supine abdominal X-ray – residual contrast from previous barium loopogram (black arrow); dilated loops of bowel (red arrow)

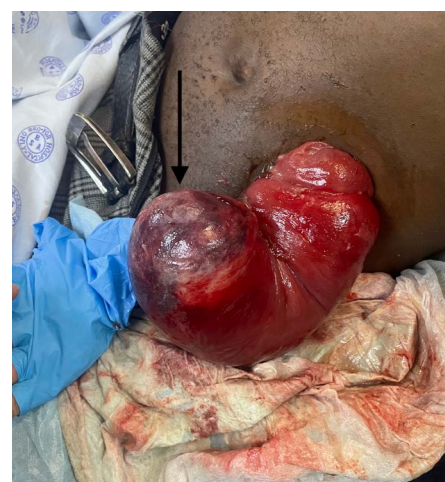

Figure 2a: Prolapsed erythematous stoma with signs of ulceration (black arrow)

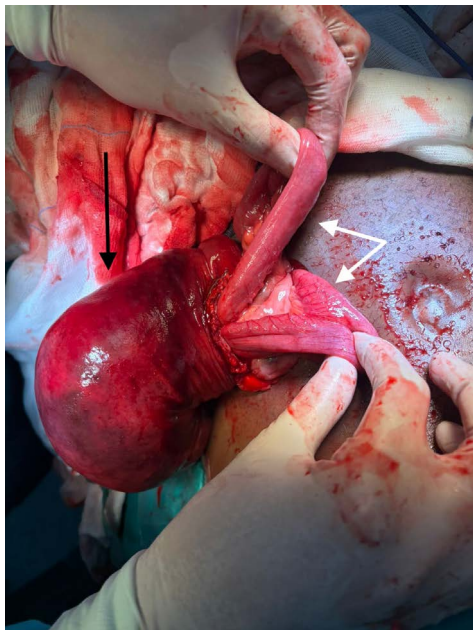


Figure 2b: Trans-stomal small bowel hernia – the proximal and distal limbs of small bowel (white arrows) can be seen herniating into the stoma resulting in the prolapse (black arrow)

Intraoperatively the prolapse was identified as the distal end of the colostomy. The stoma was separated from its mucocutaneous junction in a circumferential fashion without complication. The stoma placement was found to be lateral to the rectus muscle indicating sub-optimal placement which may have been the reason for the patient's pre-disposition to prolapse.

Upon delivery of the prolapsed colostomy, it was discovered that a 10 cm segment of small bowel had herniated through the stoma aperture and had become incarcerated between the two walls of the prolapsed large bowel (Figure 2b). The small bowel was released and revealed a clear point of obstruction. The small bowel wall appeared erythematous although not severely oedematous, and the mesentery showed signs of bruising without vascular compromise. The continuity of the incarcerated segment was intact and normal healthy peristalsis was noted. The small bowel was reduced back into the peritoneal cavity.

The prolapsed portion of the stoma showed significant oedema with early signs of ulceration. To prevent recurrence, the inflamed stoma was resected with a 60 mm endovascular gastrointestinal anastomosis (GIA) medium stapler and was reconstructed as an end colostomy. The distal colon was closed as a Hartmann's pouch.

The postoperative course was uneventful, and the stoma is functioning well. Stoma reversal is planned at a later stage.

Discussion

Stoma creation is a common procedure for the treatment of both benign and malignant bowel conditions. The complication rate of stomas is between 23–50% and range from minor, easily treatable complications, such as skin irritation, infection, dehydration and reducible prolapses to more complex problems, such as retraction, necrosis, stricture and irreducible prolapse requiring higher level of care.¹ Despite many benefits, the stoma becomes a significant part of a patient's life and has a considerable impact on their quality of life.

Stomal prolapse is a relatively common late complication occurring in approximately 2–22% of cases.¹ It occurs when a limb of bowel "telescopes" through the stomal aperture made in the abdominal wall. Risk factors include increased abdominal pressure, weakness of the abdominal fascia, redundant bowel and poor surgical techniques, such as stoma placement lateral to the rectus muscle, excessive orifice size, and significant space around the aperture.² Most cases do not require urgent surgical intervention as manual reduction can achieve resolution, failing which, application of an osmotic agent such as table sugar can help reduce bowel oedema for easier reduction.¹ Where the prolapse is irreducible, surgery can be done via local refashioning or via an open laparotomy, if necessary. It is infrequent for stomal prolapse to present with incarceration, hence appropriate clinical judgement is important to establish an underlying cause.

Stomal herniation on the other hand, has a variable incidence of 14.1–40%.¹ It is also rarely a surgical emergency. It is a type of incisional hernia occurring in the vicinity of a stoma; however, it is poorly defined due to its clinical variability. Increased abdominal pressure, increasing age (> 60 years), obesity, chronic cough, cancer, and local infection are risk factors for stomal herniation. Surgical factors include inadequate preoperative marking

Table I: Current documented cases of trans-stomal herniations

Case report (author)	Type of bowel Herniated	Type of stoma	Necrosis present or absent	Colonic perforation of stoma or none	Underlying bowel disease	Precipitating Factor
Daniell ⁷	Small bowel	End descending colostomy	Present	None	Distal sigmoid adenocarcinoma	Respiratory problems (pleural effusion)
Villa et al. ⁸	Small bowel (jejunum)	Transverse loop colostomy	Absent	Colonic perforation	Rectal neoplasm	Vomiting
Guner et al. ⁶	Small bowel	End descending colostomy	Absent	Colonic perforation	Ischemic colitis	Abrupt prolapse
Miller et al. ⁵	Small bowel	End transverse colostomy	Present	None	Adenocarcinoma	Coughing
Cecire et al. ⁴	Small bowel	End colostomy	Absent	Colonic perforation	Crohn's disease	Blunt force trauma
Abe et al. ³	Small bowel (ileum)	Sigmoid end colostomy	Absent	Colonic perforation	Endometrial cancer with infiltration of the rectum	Vomiting
Shaikh et al.	Small bowel	Sigmoid loop colostomy	Absent	None	None	Coughing

of stoma placement, urgency of surgery and size of the stomal aperture.² There are two types of stomal herniation – parastomal and trans-stomal. Typically, in the case of parastomal herniation, a bulge adjacent to or surrounding the stoma can be clinically palpated. The rarer trans-stomal herniations are more difficult to detect as they often mimic a stomal prolapse making them more challenging to diagnose.

To date, only six cases of trans-stomal herniation have been documented (Table I).³⁻⁸

The above cases underscore the contribution that increased abdominal pressure has on the development of complicated stomas. It also highlights the effect that underlying diseased bowel, seen in malignant/inflammatory conditions, has on the likelihood of stomal perforations. Our case presented a clinical challenge as we did not anticipate small bowel herniation due to its rarity. In cases describing trans-stomal herniation the diagnosis was made preoperatively by observing small bowel evisceration via a stomal perforation.^{3-5,8}

Our patient, in contrast to previous publications, is a healthy male with no underlying inflammatory process and no previous cancer. In addition, his bowel was healthy with no signs of necrosis or perforations.

He initially presented with a chronic stoma prolapse. Exercising good judgement when fashioning stomas can help reduce the risk of stoma prolapse. Strategies include choosing the correct type of stoma and ensuring the stoma is placed within the rectus sheath to decrease prolapse rates.² Further strategies to mitigate stomal prolapse include methods to secure the intestine or to reduce the space around the stoma.² Prophylactic mesh placements have been gaining popularity in recent research.^{9,10}

Learning points include the importance of ensuring adequate placement of stomas and having a high index of suspicion for trans-stomal herniation when a stomal prolapse cannot be easily reduced.

Conflict of interest

The authors declare no conflict of interest.

Funding source

No funding was required.

Ethical approval

The authors declare that this submission is in accordance with the principles laid down by the Responsible Research

Publication Position Statements as developed at the 2nd World Conference on Research Integrity in Singapore, 2010.

Informed consent was obtained from the patient included in the study.

ORCID

N Shaikh  <https://orcid.org/0009-0003-4195-1224>

RV Blanco  <https://orcid.org/0000-0001-8993-1925>

M Vente  <https://orcid.org/0009-0000-9011-544X>

R Ebrahim  <https://orcid.org/0009-0004-9971-1212>

REFERENCES

1. Kwiat M, Kawata M. Avoidance and management of stomal complications. *Clin Colon Rectal Surg.* 2013;26(02):112-21.
2. Maeda K. Prolapse of intestinal stoma. *Ann Coloproctol.* 2022;38(5):335-42. <https://doi.org/10.3393/ac.2022.00465.0066>.
3. Abe K, Yamai D, Katsumi C, Oyamatsu M, Sato K. Incarcerated small bowel herniation in a stoma mimicking sigmoid end colostomy prolapse. *Case Rep Gastroenterol.* 2024;18(1):21-7. <https://doi.org/10.1159/000535988>.
4. Cecire J, Sarkar A, Ross W, Sutherland A. Colonic perforation and trans-stomal evisceration of small bowel. *J Curr Surg North Am.* 2021;11(2):46-50. <https://doi.org/10.14740/jcs438>.
5. Miller RL, Yeung D, McCluney S, Warren OJ. Unique case of herniated small bowel infarction within a colonic stomal prolapse. *BMJ Case Rep.* 2017;bcr-2017-220850. <https://doi.org/10.1136/bcr-2017-220850>.
6. Guner A, Kahraman I, Ozkan OF, Aktas A, Kece C. Trans-stomal small bowel evisceration after colonic perforation secondary to ischemic colitis. *Case Rep Surg.* 2012;2012:1-3. <https://doi.org/10.1155/2012/560683>.
7. Daniell SJ. Strangulated small bowel hernia within a prolapsed colostomy stoma. *J R Soc Med.* 1981;74(9):687-8. <https://doi.org/10.1177/014107688107400913>.
8. Villa M, Iannelli E, Grande M, Rossi P, Tucci G. An unusual case of small intestine evisceration through a transverse loop colostomy. *Colorectal Dis.* 2011;14(1):e27-8. <https://doi.org/10.1111/j.1463-1318.2011.02749.x>.
9. Styliński R, Alzubedi A, Rudzki S. Parastomal hernia: current knowledge and treatment. *Videosurgery and other Miniinvasive Techniques. Wideochir Inne Tech Maloinwazyjne.* 2018;13(1):1-8. <https://doi.org/10.5114/wiitm.2018.72685>.
10. Israelsson LA. Preventing and treating parastomal hernia. *World J Surg.* 2005;29(8):1086-9. <https://doi.org/10.1007/s00268-005-7973-z>.